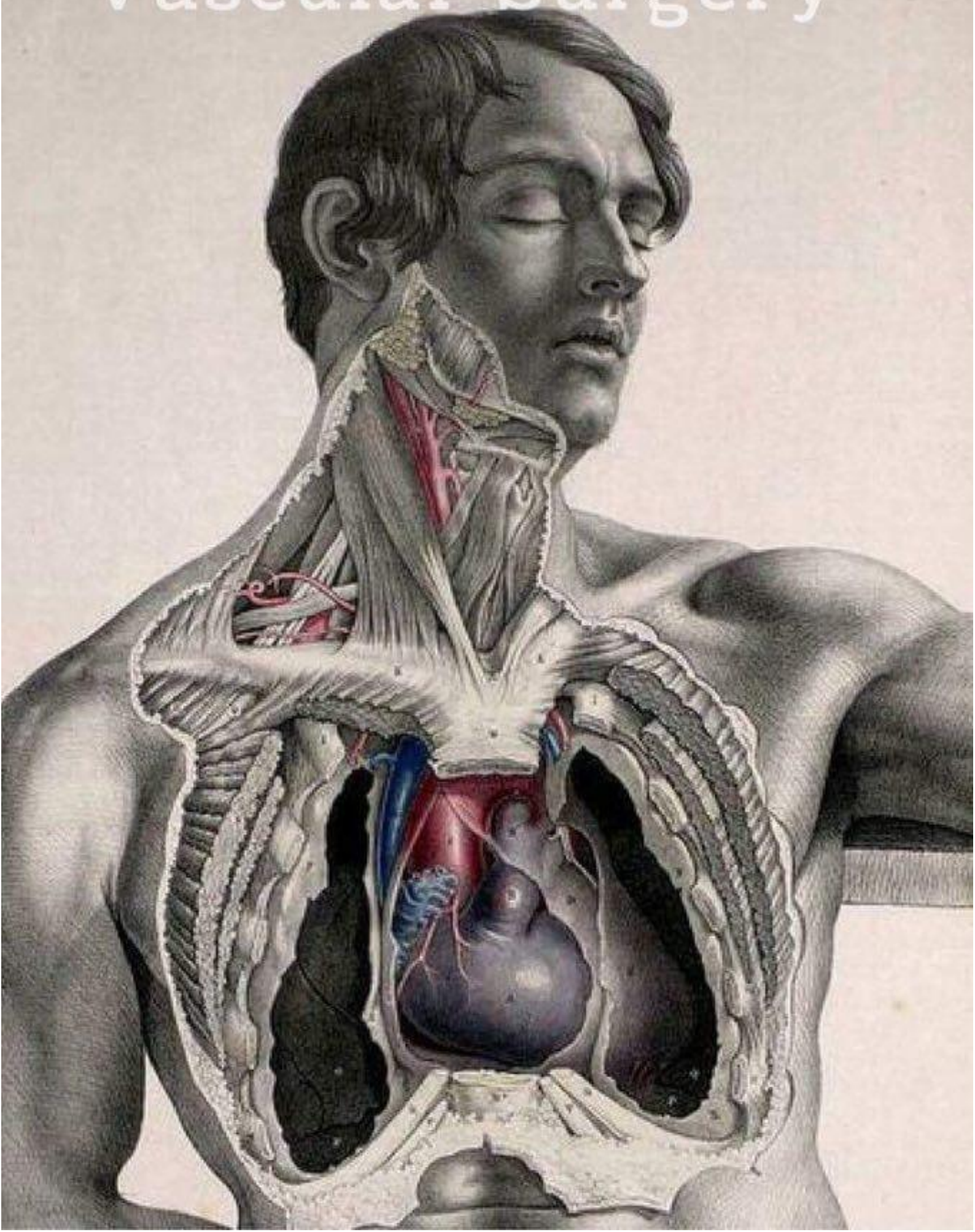


# Cardiothoracic and Vascular Surgery



**Editors:**

Aya Qteish

Ayat M. Zghoul

Bushra Arafa Zayed

Hashim Ahmad

Majd Al Rawashdeh

Malak Al-Kasasbeh

Mohammad Qussay Al-sabbagh

Tala J. Rawashdeh

**Designed by:**

Mohammad qussay al-Sabbagh

Yousef Al-As3d

## TABLE OF CONTENTS

<b>CHAPTER 1 (THORACIC SURGERY)</b> .....	3
CHEST WALL PROBLEMS .....	4
CHEST TRAUMA .....	13
MEDIASTINAL MASSES.....	22
<b>CHAPTER 2(CARDIAC SURGERY)</b> .....	36
INTRODUCTION .....	37
CARDIOPULMONARY BYPASS .....	46
CORONARY ARTERY DISEASE .....	51
VALVULAR DISEASE .....	61
PROSTHETIC HEART VALVES .....	76
CONGENITAL HEART DISEASES .....	80
<b>CHAPTER 3(VASCULAR SURGERY)</b> .....	103
AORTIC DISEASE.....	104
ABDOMINAL AORTIC ANEURYSM .....	112
PERIPHERAL ARTERIAL DISEASE .....	119
PERIPHERAL VASCULAR INJURY .....	127
PERIPHERAL VENOUS DISEASE.....	135
ARTERIAL & VENOUS ULCERS .....	141
CENTRAL VENOUS LINES & AV SHUNTS.....	143

# Thoracic surgery

- Chest wall problems: page 4
  - Written by: Mohammad Qussay Al-Sabbagh.
- Chest Trauma: page 13
  - Written by: Tala J. Rawashdeh
- Mediastinal masses: page 22
  - Written by: Bushra Arafa Zayed.
  - Corrected by: Majd Al Rawashdeh

# Chest Wall problems

## Pneumothorax



### INTRODUCTION

⚡ **Pneumothorax** is the presence of air in the pleural cavity, leading to separation of the visceral and parietal pleura.

- This results in abnormal pulmonary mechanics that can progress to tension pneumothorax, which causes cardiac compromise and is a true emergency.



### ETIOLOGY

⚡ Pneumothoraces may be spontaneous, iatrogenic, or due to trauma:

1. **Spontaneous pneumothoraces** are usually caused by the rupture of an apical bleb.
  - The typical patients are tall young males who present with acute shortness of breath and chest pain.
  - Older patients usually have significant parenchymal disease, such as emphysema. These patients present with a ruptured bulla and can have a more dramatic presentation, including tachypnea, cyanosis, and hypoxia.
  - Other etiologies of spontaneous pneumothorax include cystic fibrosis (CF) and, rarely, lung cancer. The risk of ipsilateral recurrence of a spontaneous pneumothorax is 50%, 62%, and 80% after the first, second, and third episodes, respectively, if managed conservatively without surgery.
2. **Iatrogenic pneumothoraces** are usually the result of pleural injury during central venous access attempts, pacemaker placement, or transthoracic or transbronchial lung biopsy.
3. **Traumatic pneumothoraces** will be discussed later.





## CLINICAL FEATURES

⚡ **Symptoms:** pleuritic chest pain, dyspnea, and tachypnea.

⚡ **Physical examination** demonstrates decreased breath sounds on the involved side. Examination for signs of tension pneumothorax, including deviation of the trachea to the opposite side, respiratory distress, and hypotension, must be performed.



## DIAGNOSIS

⚡ An upright chest x-ray (CXR) can establish the diagnosis of pneumothorax

- However, confirming the diagnosis of tension pneumothorax is unnecessary and leads to dangerous delays.
- Smaller pneumothoraces may only be evident on expiratory CXRs or CT scan.



## TREATMENT

⚡ Management options include observation, aspiration, needle thoracostomy, chest tube placement with or without pleurodesis, and surgery.

1. **Observation** is an option in a healthy, asymptomatic patient with a small pneumothorax.
  - Supplemental oxygen may help to reabsorb the pneumothorax by affecting the gradient of nitrogen in the pneumothorax.
2. **Aspiration of the pneumothorax** may be performed using a small catheter attached to a three-way stopcock. This should be reserved for small to moderate pneumothoraces with low suspicion of an ongoing air leak.
3. **Needle thoracostomy** should be performed for suspected tension pneumothorax in the setting of hemodynamic compromise. A large-bore IV catheter (14 to 16 gauge) is placed in the second intercostal space in the mid-clavicular line, with the needle advanced until air is freely aspirated into a syringe. The needle is then removed, and the catheter is kept open and in place until a formal chest tube is expeditiously placed.
4. **Percutaneous catheters** are essentially mini chest tubes that may be placed using Seldinger technique. Multiple commercial kits exist and allow for the catheter to be placed to a water seal or suction. The catheters are of small caliber, so use is limited to situations of simple pneumothorax. If there is

concern for lung adhesions, bedside percutaneous catheters should be avoided.

5. **Tube thoracostomy** remains the gold standard for large pneumothoraces, associated effusion, or when there is an expected need for pleurodesis. Chest tubes may be connected to a Heimlich one-way valve, a simple underwater-seal system, or to vacuum suction (typically -20 cm). If the water-seal chamber bubbles with expiration or with coughing, it is evident that an air leak persists.
6. **Bedside pleurodesis.** Sclerosing agents may be administered through the chest tube to induce fusion of the parietal and visceral pleural surfaces. Doxycycline, bleomycin, and talc have all been described. Bedside pleurodesis can be associated with an inflammatory pneumonitis in the lung on the treated side. In patients with limited pulmonary reserve, this may present as clinically significant hypoxia.
7. **Surgery** is performed using a video-assisted thoracoscopic surgery (VATS) or rarely via thoracotomy.
  - Operative management consists of stapled wedge resection of blebs or bullae, usually found in the apex of the upper lobe or superior segment of the lower lobe.
  - Pleural abrasion (pleurodesis) should be performed to promote formation of adhesions between visceral and parietal pleurae. In older patients, intraoperative talc insufflation in the pleural space provides reliable pleurodesis.

Indications for operation for pneumothorax include:

1. Recurrent spontaneous ipsilateral pneumothoraces.
2. Bilateral pneumothoraces
3. Persistent air leaks on chest tube suction (usually >3 to 5 days)
4. First spontaneous pneumothorax in patients with high-risk occupations (e.g., pilots and

## Plural effusion

### INTRODUCTION

✦ **Pleural effusions** are buildup of fluid in the pleural space.

## ? ETIOLOGY

✦ Pleural effusions may result from a wide spectrum of benign, malignant, and inflammatory conditions.

- They are broadly categorized as either **transudative** (protein-poor fluid from increased intravascular pressure) or **exudative** (protein or cell rich fluid resulting from increased vascular permeability).

## 🔍 CLINICAL FEATURES

✦ Presenting symptoms of pleural effusions can include dyspnea, cough, or pleuritic chest pain, as well as a variety of symptoms specific to the underlying etiology. Small pleural effusions are often asymptomatic.

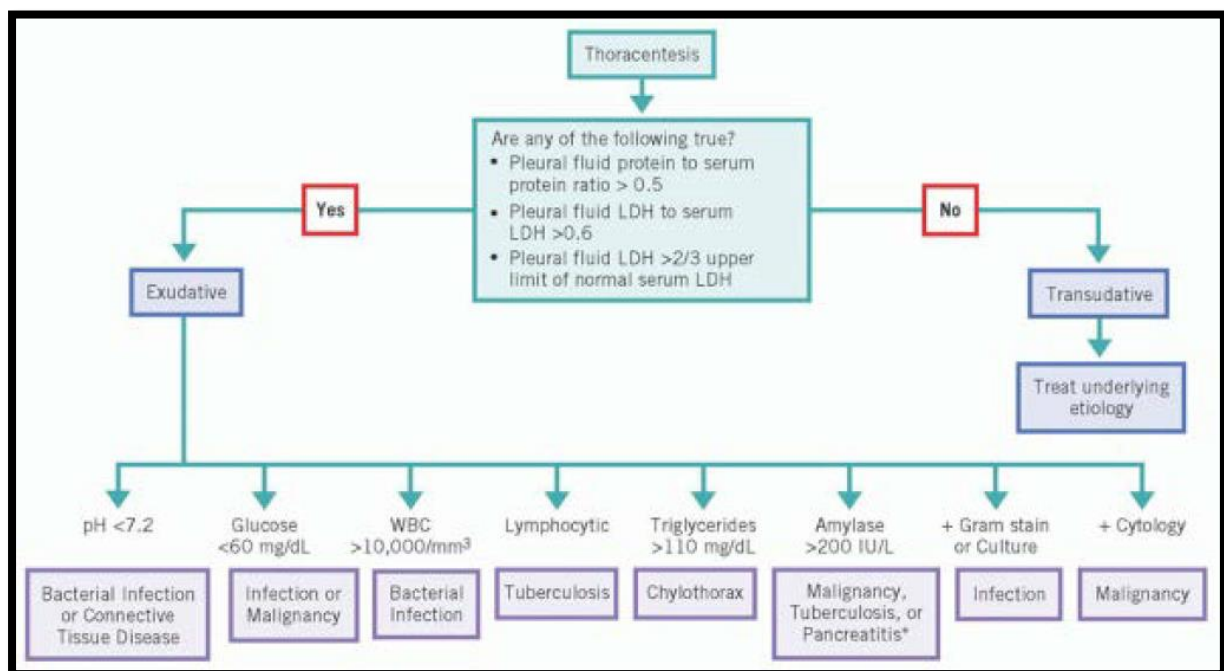
## 💡 DIAGNOSIS

✦ Most pleural effusions are first diagnosed on **CXRs**.

- CT scan and ultrasound can be helpful if history suggests a more chronic organizing process such as empyema.

✦ **Thoracentesis** is frequently used to evaluate large, recurrent, or symptomatic pleural effusions.

- The fluid should be sent for pH, glucose, amylase, lactate dehydrogenase (LDH), protein levels, culture and Gram stain, a differential cell count and cytology, to aid in diagnosis (see the figure below):





- Appearance of the fluid often indicates etiology: Thin yellow or clear fluid is common with transudative effusions; cloudy, foul-smelling fluid usually signals infection; milky white fluid suggests chylothorax.



## TREATMENT

⚡ **Transudative pleural effusions** are considered a secondary diagnosis; therefore, therapy should be directed at the underlying problem (e.g., congestive heart failure, cirrhosis, or nephrotic syndrome). PleurX indwelling catheters can be used for drainage of recurrent symptomatic effusions.

⚡ **Exudative pleural effusions** may be broadly classified based on whether the cause is benign or malignant.

1. **Benign exudative effusions** are often a result of pneumonia (parapneumonic). They can also be a true empyema, tuberculous, chylous, or pancreatic reactive effusions.
  - Treatment of parapneumonic and tuberculous effusions is adequate pleural drainage and appropriate antibiotics.
  - Chylothorax can be controlled with diet changes and drainage, pleurodesis, or thoracic duct ligation.
  - A pancreatic reactive effusion usually disappears with resolution of the pancreatitis.
2. **Malignant effusions** are most often associated with cancers of the breast, lung, and ovary and with lymphoma. Diagnosis is often made by cytology. In the event that cytology is not diagnostic, pleural biopsy may be indicated. Given the overall poor prognosis in these patients, therapy offered by the thoracic surgeon is generally palliative, by:
  - **Drainage** of effusion to alleviate dyspnea and improve pulmonary mechanics by reexpanding the lung is performed with a PleurX catheter.
  - **Pleurodesis**, usually with talc, can prevent reaccumulation of the effusion.

# empyema



## INTRODUCTION

✦ **Empyema** is invading of the pleural space with bacteria which result in accumulation of pus.

✦ Classification:

- **Stage 1:** Exudative, with swelling of the pleural membranes as a result of ↑ permeability of swollen membranes (Uncomplicated Acute stage).
- **Stage 2:** Fibropurulent(Transitional)with heavy fibrin deposits.
- **Stage 3:**Organizing or Chronic phase. With ingrowth of fibroblast and deposition of collagen



## ETIOLOGY

✦ Fifty percent of empyemas are complications of pneumonia (**parapneumonic**) ;25% are **complications** of esophageal, pulmonary, or mediastinal surgery; and 10% are extensions from **subphrenic** abscesses.

✦ Common Gram-positive bacteria are Staphylococcus aureus and Streptococci, Gram-negative bacteria are Escherichia coli, Pseudomonas, and Klebsiella, and anaerobic bacteria are Bacteroides species.



## CLINICAL FEATURES

✦ Presentation of empyema ranges from chronic loculated effusion in a patient with fatigue to systemic sepsis requiring emergent care.

- Other symptoms include pleuritic chest pain, fever, cough, and dyspnea.



## DIAGNOSIS

✦ **CBC:**↑ WBC with shift to left,↑ CRP ESR.

✦ **CXR:** Effusion,↑thickness of the pleura, Air fluid level.

✦ **Ct scan:**

- Localize collection.
- Identify the underlying parenchymal disease.

- Distinguish it from lung abscess.
- Fluid density, loculations.

⚡ **Thoracentesis:** Empyema fluid characteristics:

- PH <7.0
- Glucose < 40 mg/dL
- LDH > 1000 IU/dL
- Positive Gram stain
- Positive culture (50%)
- Specific gravity > 1.018
- WBC > 500 cells/mm<sup>3</sup>
- Protein > 2.5 g/dL



## TREATMENT

⚡ Management includes control of the infection by appropriate antibiotics, drainage of the pleural space, and obliteration of the empyema space.

1. **Early or exudative empyema** is usually adequately treated with simple tube drainage.
2. **Fibropurulent empyema** may be amenable to tube drainage alone, but the fluid may be loculated and may require thoroscopic drainage.
3. **In advanced or organizing empyema**, the fluid is thicker, and a fibrous peel encases the lung. Thoracotomy may be necessary to free the entrapped lung. If a patient has a persistent fluid collection with an adequately placed tube as evidenced by chest CT, intrapleural fibrinolytic therapy may be useful to break down thin adhesions. Failure of intrapleural fibrinolytics usually requires operative intervention.

# Lung abscess



## INTRODUCTION

⚡ **Lung abscess:** Subacute pulmonary infection in which the chest -X ray shows cavity within the lung parenchyma.

## ? ETIOLOGY

✦ primary:

- Aspiration: The most frequent.
- Post-Pneumonic.

✦ secondary:

- Obstructing carcinoma.
- COPD
- Metastatic from extrathoracic source septicemia.
- F.B aspiration.
- Pulmonary infarctions.

✦ The individuals with high risk: alcohol abuse, history of Aspiration, Old TB, Epilepsy, drug abuse, COPD.



## DIAGNOSIS

✦ **Symptoms:** Fever, intermittent & night sweats chills. Purulent Foul-smelling sputum is highly suggestive.

✦ **history** of Aspiration, Sepsis.

✦ **Signs:** Tachypnea, consolidation, local chest wall tenderness.

✦ **Investigations:**

1. **CXR:** Pneumonitis pattern, early lesions → Air-fluid level.
2. **sputum analysis & culture.**
3. **CT-scan.**
4. **Fibrooptic Bronchoscopy** is mandatory, to:
  - Take samples for culture.
  - Rule out endobronchial tumor or obstruction.
  - To assess if can be drained internally.



## TREATMENT

✦ **Antibiotics** for 6-8 weeks to identify the organism.

✦ **Drainage:**

1. Chest physiotherapy.
2. Bronchoscopy: internal drainage or indwelling transbronchial catheter drainage.
3. Percutaneous cath. Drainage.

⚡ **External drainage, by:**

- Chest tube thoracostomy.
- CT-guided catheter.
- Open pneumonostomy (MONALDI procedure.)

⚡ **Surgery (lobotomy), indications for surgery:**

1. Acute: for complications
  - Bronchopleural fistula.
  - Empyema.
  - Hemoptysis. (Massive)
2. Chronic: Definitive treatment.
  - Persistent symptoms despite long term Antibiotics therapy.
  - Suspicious of carcinoma.
  - Complications: Empyema, bronchopleural fistula.
  - Persistent cavity >6 cm after ABO therapy.

Indications for external drainage:

- If remain septic.
- Failure to wean from mechanical ventilation.
- Soiling of the contralateral lung.
- Abscess cavity >4 cm & under tension on CXR.
- ↑ size while on ABO.



# Chest Trauma

## Tension Pneumothorax



### INTRODUCTION

**Definition:** It is the progressive build-up of air within the pleural cavity as a result of a 'one-way valve' air leak either from the lung or through the chest wall.

**It is a life threatening condition.**



### ETIOLOGY

It mostly commonly results from:

- (1) penetrating chest trauma,
- (2) blunt chest trauma with parenchymal lung injury,
- (3) rib fractures,
- (3) other causes such as puncturing the lung while placing a central venous catheter, and mechanical positive pressure ventilation.



### PATHOPHYSIOLOGY

Disruption of the lung parenchyma or parietal pleura acts as a one-way valve; during inspiration air is drawn into pleural space, and during expiration the tissue valve prevents air from escaping.

As the air gathers up within the pleural cavity without any means of escape, it completely collapses and compresses the affected lung.

Furthermore, the intrapleural pressure on the affected side increases to the point where it displaces the mediastinum to the opposite side, this displacement leads to the kinking of the vena caval vessel roots, decreasing the venous return and leading to a state of hemodynamic instability (hypotension and hypoperfusion).

It also compresses the lung on the opposite side.



## CLINICAL FEATURES

**Symptoms:** pleuritic chest pain, dyspnea, and tachypnea.

**Signs:** anxiety, distended neck veins, tracheal deviation away from the affected side (late finding, and is not necessary to clinically confirm diagnosis), hyper-resonance and absent breath sounds over the affected side.

**Complications:** respiratory failure, low blood oxygen, shock and cardiac arrest.



## DIAGNOSIS

Patients usually present to the ER with a history of chest trauma complaining of SOB of an abrupt onset and chest pain that worsens on inspiration.

Differential diagnosis based on history and presentation:

- Pneumothorax
- Rib fracture
- MI
- Acute pulmonary embolism

On physical examination patients are usually hypotensive, tachycardic, tachypneic with a decreased arterial O<sub>2</sub> saturation.

Asymmetric chest wall with no flail movement, and jugular vein distention might be notable,

Local tenderness over the injured area, and a tracheal deviation away from the affected side,

Decreased breath sounds and hyper-resonance over the affected side.

Based on physical examination, now the differential diagnosis is:

- Tension pneumothorax.

Diagnosis of tension pneumothorax is based on clinical presentation, and treatment should never be delayed by waiting for radiological confirmation.

Further investigation tools ordered at time of presentation: CXR (confirmatory) and lab tests which include ABGs and cardiac enzymes (important to rule out MI).



## TREATMENT

Immediate decompression through the insertion of a large-bore needle into the second intercostal space in the midclavicular line of the affected side. This is known as needle thoracostomy.

This is followed later on by insertion of a chest tube in the fourth or fifth intercostals space in the anterior axillary line.

# Open Pneumothorax



## INTRODUCTION

**Definition:** a life threatening condition in which a large open defect in the chest wall leads to inadequate ventilation and a progressive build-up of air within the pleural cavity.



## ETIOLOGY

It is due to a penetrating chest wall injury that results in a defect that is more than 3 cm in size (OR more than 2/3 tracheal diameter.)

## PATHOPHYSIOLOGY

During inhalation, the negative intra-thorax pressure generated by inspiration causes the air to get sucked into the pleural cavity through the chest wall defect; the air preferentially passes through the defect rather than the trachea due to lower resistance to the flow. This leads to hypoventilation and a secondary hypoxia.

The progressive accumulation of air within the cavity also results in compression of the lung and displacement of the mediastinum.

## CLINICAL FEATURES

- Signs and symptoms are proportionate to the size of the defect.

**Symptoms:** Dyspnea (most commonly), chest pain.

**Signs:** hyper-resonance, absent breath sounds, and tracheal deviation.

**Complications:** respiratory failure, shock etc... (complications of pneumothorax)

## DIAGNOSIS

Patient presents to the ER with a history of penetrating chest trauma complaining of the shortness of breath

On physical examination, signs are typical of pneumothorax;

- Tachypneic, tachycardic, hypotensive and decreased O<sub>2</sub> saturation,
- Asymmetric chest wall, and usually there is visible bubbling around the wound,
- Local tenderness over the injured area, and tracheal deviation away from the affected side,
- Decreased breath sounds and hyper-resonance over the affected side.

Diagnosis is based on clinical presenting symptoms, early management is crucial.



## TREATMENT

Initial management consists of closing the wound with a sterile plastic dressing, taped on three sides to act as a flutter-type valve.

- A flutter valve effect allows air to escape from but not enter the thoracic cavity.

A chest tube is then inserted in a site distant from the wound site. A common problem is using a tube that is too small, use a tube that is  $\geq 28$ FG in an adult.

Definitive treatment may necessitate wound debridement and closure, and early referral.

# Massive Haemothorax



## INTRODUCTION

**Definition:** The accumulation of blood in the pleural cavity as a result of blunt or penetrating chest wall injury. To call it “massive”, the chest tube inserted in the hemithorax drains  $>1.5$  L of blood on initial placement.



## ETIOLOGY

It is commonly due to chest trauma. Also, it may be a result of rib fracture, lung parenchymal injury and venous injuries.



## PATHOPHYSIOLOGY

As a result to the trauma, blood vessels (intercostals or occasionally the internal mammary artery) present in the chest wall or pleura are torn and begin to bleed



into the pleural cavity. This accumulation of blood can significantly compromise respiratory function; compressing the lung and impeding proper ventilation,

As well as hemodynamic function; due to blood loss and the possibility of developing hemorrhagic shock.



## CLINICAL FEATURES

**Symptoms:** chest pain, dyspnea, tachypnea and tachycardia.

**Signs:** anxiety, flat neck veins in supine position, pale and cool skin, absent breath sounds on affected side and dullness on percussion.

**Complications:** empyema, fibrothorax and shock.



## DIAGNOSIS

Diagnosis is based on clinical presentation, patient is cold, tachycardic, and hypertensive due to blood loss. In addition to that, there will be reduced breath sounds over the injured hemithorax due to lung collapse, and the percussion note will be dull.

So shock associated with reduced breath sounds and dull percussion.



## TREATMENT

The initial management consists of correcting the hypovolaemic shock (crystalloids followed by type specific blood) and insertion of an intercostal drain.

Initial drainage of more than 1.5 L of blood, OR ongoing hemorrhage of more than 200 mL/hour over 3-4 hours is considered an indication for urgent thoracotomy.

# Pericardial Tamponade



## INTRODUCTION

**Definition:** Accumulation of blood within the pericardial sac producing physiological obstruction of the heart.

## ? ETIOLOGY

It is most commonly the result of penetrating chest trauma.

- All patients with penetrating injury anywhere near the heart with manifestations of shock must be considered to have a cardiac injury until proven otherwise.

## ⚡ PATHOPHYSIOLOGY

As a result of the accumulation of blood within the pericardial space, pericardial pressure rises. In attempt to prevent cardiac chamber collapse, ventricular diastolic, right atrial and wedge pressure all rise to equalize the pressure difference. This gives rise to the hemodynamic hallmarks of pericardial tamponade.

- Pulsus paradoxus: the exaggerated drop in systolic blood pressure during inspiration ( $>10$  mmHg) is seen in this condition; when the pericardium is stretched, full of blood and inelastic, typical respiratory variation in left and right ventricular filling is greatly exaggerated. Inspiration increases negative intra-thoracic pressures and increases venous return to the right heart. This increased volume in the right heart pushes the intra-atrial and intra-ventricular septa into the left heart and thus, the volumes within the left heart will be decreased with inspiration, resulting in decreased systemic cardiac output and a drop in systemic blood pressure.

## 🔍 CLINICAL FEATURES

**Symptoms:** difficulty breathing, tachycardia, and chest pain.

**Signs:** Beck's triad: low arterial blood pressure, distended neck veins (elevated venous pressure), and muffled heart sounds. Pulsus paradoxus.

**Complications:** pulmonary edema and shock (due to cardiac compression and not hypovolemia).



## DIAGNOSIS

Clinical diagnosis; elevated venous pressure, reduced arterial pressure, muffled heart sounds (these 3 are known as Beck's triad), and most importantly the patient will not be responsive to fluid administration (cardiogenic shock).

If the situation allows, an echocardiogram can be useful to see the blood as well as a focused assessment sonogram in trauma (FAST scan).



## TREATMENT

The correct immediate treatment of tamponade is pericardiocentesis (aspiration).

If the bleeding is minimal this will probably be enough to relieve the immediate symptoms, but if the bleeding was major, there might be a need for operative intervention through sternotomy or left thoracotomy.

# Flail Chest



## INTRODUCTION

**Definition:** disruption of the integrity of the thoracic cage defined as 3 or more ribs fractured in 2 or more places, usually from a blunt trauma to the chest.

- A life threatening condition.



## ETIOLOGY

Commonly to due to a severe blunt trauma, such as a car accident or a serious fall. Elderly people are more prone to be affected due to age-related weakness, and people with bone diseases.

## PATHOPHYSIOLOGY

The thoracic cage is the skeleton of the thoracic wall and therefore serves to support the thorax.

In a flail chest, the segment of the chest wall that is situated between the originally supporting ribs becomes loose, and on inspiration it is displaced inward paradoxical to the rest of the chest wall which expands outwardly. As a result, less air moves in.

In addition to that, the blunt force required typically produces an underlying pulmonary contusion.

Both mechanical impairment of thoracic wall movement and the accompanying lung injury all contribute to the developing hypoxia.

- High risk of developing pneumothorax or haemothorax.

## CLINICAL FEATURES

**Symptoms:** severe chest pain, and breathing difficulty.

**Signs:** bruising and discoloration over the chest area, abnormal movement of the chest during respiration (paradoxical motion and asymmetry), tenderness over the injured area.

**Complications:** hypoxia, pneumothorax and haemothorax.

## DIAGNOSIS

Diagnosis is based on clinical presentation ( signs and symptoms).

## TREATMENT

Consists of oxygen administration, adequate analgesia and physiotherapy.

**Surgical (to stabilize the flail chest):** may be useful in a selected group of patients with isolated or severe chest injury and pulmonary contusion.

# Mediastinal masses

## ❖ Mediastinal anatomy:

Mediastinum is the median space of the chest cavity extending from its inlet to its outlet, and is bounded on each side by pleura and lung.

For the purpose of description, it is divided into:

### 1) Superior mediastinum:

It is the area above an imaginary line extending from the sternal angle to the lower border of 4th thoracic vertebra (inferiorly) up to the thoracic inlet (superiorly). It extends from the manubrium sterni (anteriorly) to the vertebral column (posteriorly).

❖ Contents: aortic arch and its related structures.

### 2) Inferior mediastinum:

#### ➤ Boundaries:

- Anteriorly: body of the sternum
- Posteriorly: lower 8 thoracic vertebrae (T5-T12)
- Superiorly: the imaginary line which extends from the sternal angle to the lower border of 4th thoracic vertebra
- Inferiorly: thoracic outlet (closed by the diaphragm)

#### ➤ It is divided into 3 parts :

**a-** Anterior mediastinum: anterior to the heart.

#### ❖ contents:

- Thymus gland.
- substernal extension of the thyroid and parathyroid gland.
- Lymphatic tissues.
- Fat.

**b-** Middle mediastinum:

#### ❖ contents:

- Heart.
- Pericardium.
- Aortic arch and its major branches.
- Innominate veins and superior vena cava.

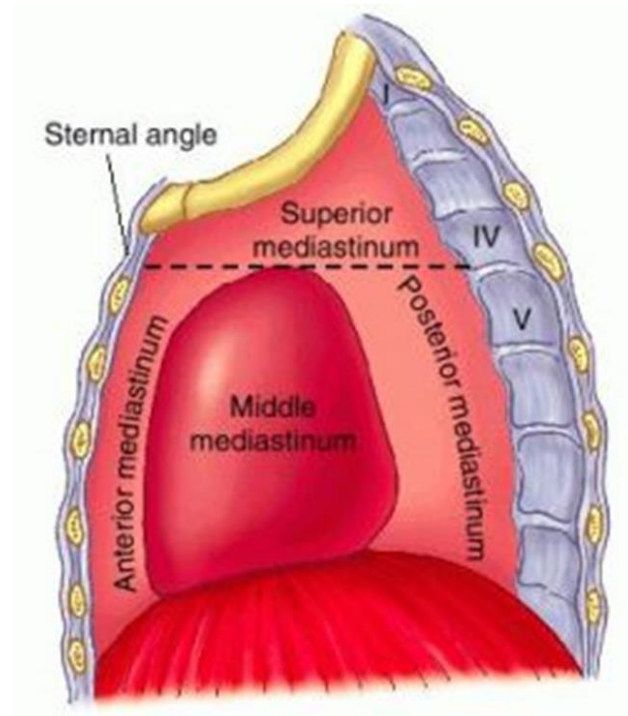
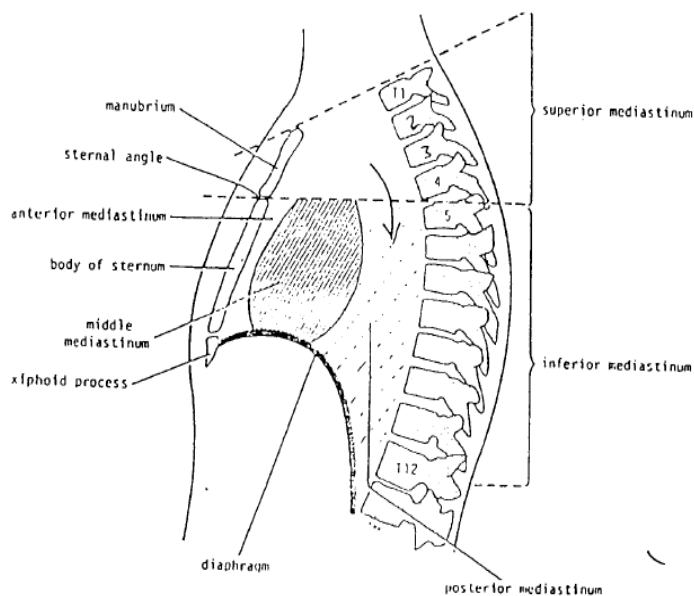


- Pulmonary arteries and hila.
- Trachea
- Lymph nodes.
- phrenic and upper vagus nerve.

**c- Posterior mediastinum: posterior to the heart**

❖ contents:

- Esophagus.
- Descending aorta.
- Azygos and hemi-azygos vein.
- Paravertebral lymph nodes.
- Thoracic duct.
- Lower portion of the vagus nerve and the sympathetic chain.



# Mediastinal masses

## INTRODUCTION

Benign or malignant mediastinal masses can develop from structures (1) that are normally located in the mediastinum or (2) that pass through the mediastinum during development, as well as from (3) metastases of malignancies that arise elsewhere in the body.

*We will go firstly through a general discussion of mediastinal masses regardless what is their nature or what they are. Then we will discuss some of the differentials in more details.*

*NOTE: you can find mediastinal anatomy in the introduction part of this dossier.*

### ➤ General Signs and Symptoms:

*Those that can be produced by any mass in the mediastinum due to its anatomical location rather than the nature of this mass.*

Direct involvement or compression of normal mediastinal structures cause a wide range of symptoms. These can include:

- Cough.
  - Stridor.
  - Hemoptysis.
  - Hoarseness.
  - Shortness of breath.
  - Pain.
  - Dysphagia due to compression on esophagus.
  - Facial and/or upper extremity swelling due to vascular compression (e.g. superior vena cava syndrome).
  - Hypotension due to tamponade or cardiac compression.
  - Horner syndrome due to sympathetic chain involvement.
- These are RS related symptoms.

*In addition, there may be specific symptoms that may appear according to the underlying cause. These will be mentioned with each differential diagnosis.*

➤ **Differential diagnosis:**

Differential diagnosis is different according to the location of the mass; whether it is in the anterior, middle, or posterior mediastinum.

Simply, the differential DX of each one is directly related to its contents.

❖ Differential diagnosis of the **anterior** mediastinal masses:

1. Lymphoma.
2. Teratoma
3. Germ cell tumors
4. Cystic hygromas
5. Thymic lesions

❖ Differential diagnosis of the **middle** mediastinal masses:

1. Lymphomas
2. Cysts
3. Mesenchymal tumors
4. Tracheal tumors
5. Cardiac and pericardial tumors
6. Vascular tumors
7. Lymphadenopathy

❖ Differential diagnosis of the **posterior** mediastinal masses:

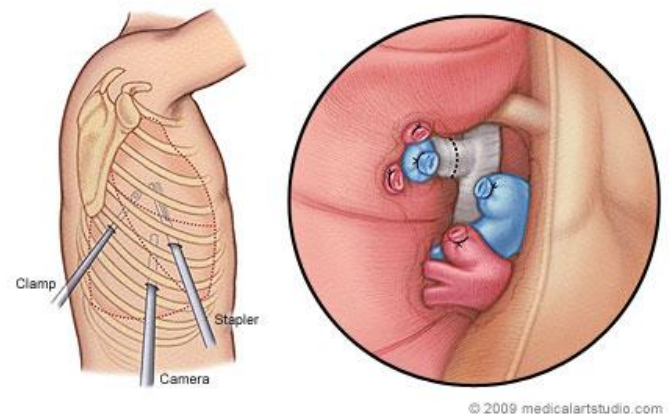
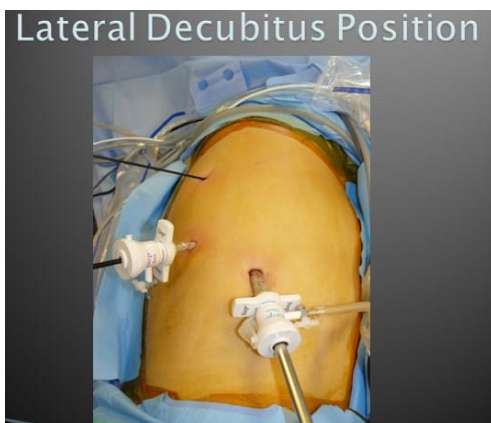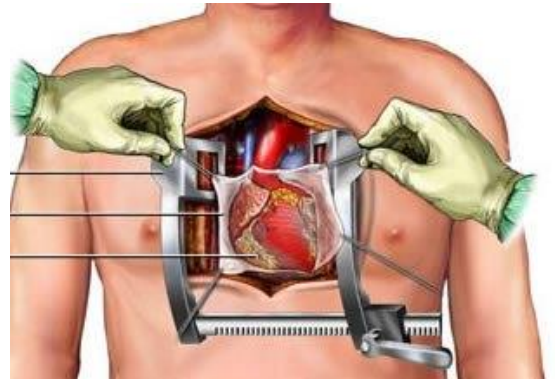
1. Lymphomas
2. Neurogenic tumors
3. Mesenchymal tumors
4. Esophageal tumors and cysts
5. Hiatal hernia
6. Thoracic duct cyst
7. Meningocele

➤ Surgery of the mediastinum:

Generally, the surgery of mediastinum includes two options:

- 1- Open median sternotomy.
- 2- Video assisted thoracoscopic surgery (VATS)

→ The **preferred** approach is a **median sternotomy** providing adequate exposure of the mediastinal structures and allowing complete removal of the thymus or any other structure.



*\*Now we will go through the most important differential diagnoses in details.\**

# \*Anterior mediastinal masses\*

## 1. Thymoma



### INTRODUCTION

#### ➤ Anatomy and histology :

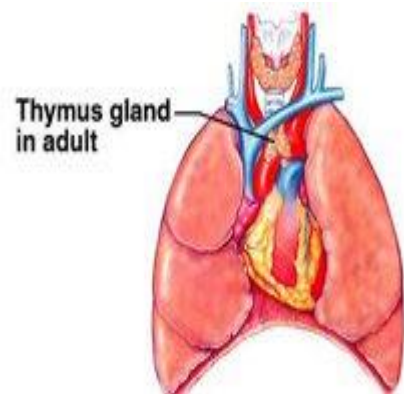Thymus is a lymphoid organ located in the anterior mediastinum. This organ is located behind the sternum in front of the great vessels; it reaches its maximum weight at puberty and undergoes involution thereafter.

In early life, the thymus is responsible for the development and maturation of cell-mediated immunologic functions. The thymus is composed predominantly of epithelial cells and lymphocytes.

#### ➤ Epidimology:

Thymic lesions account for approximately one-half of all anterior mediastinal masses and can include a range of benign and malignant pathologies.

**Thymomas** occur in patients of all ages, with a peak incidence between ages **40 to 60 years**. The gender distribution is approximately equal.



### PATHOPHYSIOLOGY

All thymomas originate from epithelial thymic cells. 4% of them consist of a pure population of epithelial cells.

Most of thymomas has morphology that shows mixture of epithelial cells and lymphocytes.

*\*Thymomas are epithelial neoplasms NOT lymphocytic ones.\**





## CLINICAL FEATURES

### ❖ Signs and symptoms:

- One third are **asymptomatic**, discovered incidentally on CXR or at autopsy.
- One third complain of **local symptoms** related to pressure or local invasion: SVC syndrome, cough, chest pain, dysphonia, dysphagia...etc
- One third have an **autoimmune diseases** (as a paraneoplastic syndromes), these include:
  1. Myasthenia gravis:
    - The most common autoimmune disease associated with thymoma is myasthenia gravis, which occurs in approximately 30 percent of patients with thymoma. Furthermore, some patients who are diagnosed with myasthenia gravis will be found to have a thymic mass on imaging.
    - Patients with a thymic mass who have not been evaluated for myasthenia gravis should be tested for anti-acetylcholine receptor antibodies.
  2. Pure red cell aplasia: is an uncommon disorder in which maturation arrest occurs in the formation of erythrocytes. *Called pure, as the WBC and platelet's production is normal.*
  3. Polymyositis
  4. Hypogammaglobulinemia



## DIAGNOSIS

### ❖ History:

Patients may present with symptoms of mediastinal masses -mentioned before- or with symptoms related to one of the paraneoplastic syndromes associated with thymomas-mentioned- .

### ❖ Physical examination:

At an early stage, patients with thymoma may have completely normal physical exam. The thoracic expansion of the tumor with invasion or compression of the SVC may cause the characteristic finding of facial and

upper extremity swelling, whereas invasion of the innominate vein will cause a predominantly left arm swelling. Phrenic nerve invasion may cause decreased breath sounds on the affected side. Most patients develop ocular findings such as ptosis or diplopia and some may have involvement of respiratory muscles.

❖ Imaging:

- **Chest (CT) scan is the imaging procedure of choice.**
- Thymic enlargement should be determined because most enlarged thymus glands on CT scan represent a thymoma.

CT scan with intravenous contrast dye is preferred;

- To show the relationship between the thymoma and surrounding vascular structures.
- To define the degree of its vascularity.
- To guide the surgeon in removal of a large tumor, possibly involving other mediastinal structures.

❖ Biopsy:

If a patient presents with atypical features or is found to have an invasive tumor and is under consideration for induction therapy, obtaining preoperative biopsy is indicated.

The limited anterior mediastinotomy or thoracoscopic approach for biopsy can be used.

❖ Staging of thymomas:

*"Masaoka Classification"*

➤ STAGE I

- **Encapsulated** tumor with no gross or microscopic invasion.
- Treatment: Complete surgical excision.

➤ STAGE II

- Macroscopic invasion into the mediastinal **fat or pleura** or microscopic invasion into the capsule.
- TREATMENT Complete surgical excision and postoperative radiotherapy to decrease the incidence of local recurrence.

- STAGE III
  - Macroscopic invasion of the pericardium, great vessels, or lung.
  - TREATMENT Complete surgical excision and postoperative radiotherapy to decrease the incidence of local recurrence.
- STAGE IVA
  - Pleural or pericardial metastatic spread.
  - TREATMENT Surgical debulking, radiotherapy, and chemotherapy.
- STAGE IVB
  - Lymphogenous or hematogenous metastases
  - TREATMENT Surgical debulking, radiotherapy, and chemotherapy

*“Benign tumors are noninvasive and encapsulated. Conversely, malignant tumors are defined by local invasion into the thymic capsule or surrounding tissue”*

*Thus we do NOT depend on histology*



## TREATMENT

The prognosis of a person with a thymoma is based on the tumor's gross characteristics at operation, not the histological appearance.

Treatment modalities:

### 1- Surgery:

- If the tumor is small and appears readily accessible, perform a total thymectomy with contiguous removal of mediastinal fat.
- If the tumor is invasive, perform a total thymectomy in addition to en bloc removal of involved pericardium, pleura, lung, phrenic nerve, innominate vein, or superior vena cava. Resect one phrenic nerve; however, if both phrenics are involved, do not resect either nerve, and debulk the area.
- NOTE: Clip areas of close margins or residual disease are used to assist the radiation oncologist in treatment planning

## 2- Chemotherapy:

The most common chemotherapy drugs in the treatment of thymoma are:

- doxorubicin
- cisplatin
- cyclophosphamide
- etoposide
- ifosfamide

## 3- Radiotherapy:

- Adjuvant radiation therapy in completely or incompletely resected stage III or IV thymomas is considered a standard of care.
- Preponderance of evidence indicates that all thymomas, except completely encapsulated stage I tumors, benefit from adjuvant radiation therapy.

Finally; Thymomas are indolent tumors that may take at least 10 years to recur; therefore, short-term follow-up will not depict relapses accurately.

## 2. Germ cell tumors

- The mediastinum is the most common location for extra-gonadal germ cell tumors in adults.
- Germ cell tumors can be either benign (teratomas, dermoid cysts) or malignant (seminomas, non-seminomatous germ cell tumors).
- Seminomas are more common than non-seminomatous germ cell tumors.
- All patients with a mediastinal mass that could be a germ cell tumor should have **alpha-fetoprotein (AFP)**, lactate dehydrogenase (LDH), and beta-human chorionic gonadotropin (beta-hCG) measured prior to any therapy, as these are elevated in non-seminomatous germ cell tumors.

### 3. Enlarged/ectopic thyroid

Intrathoracic thyroid tissue typically causes symptoms of shortness of breath or dysphagia.

The intrathoracic mass is usually **continuous** with the thyroid gland in the neck and receives its blood supply from the thyroid arteries found in the neck; only 2 percent of cases are separate from the cervical thyroid.

### 4. Lymphoma

May cause airway compression as well as superior vena cava obstruction.

Treatment mainly is chemotherapy.

It could be a Hodgkin or non-Hodgkin's lymphoma.

---

## **\*Middle mediastinal masses\***

### 1. Lymphadenopathy

Lymphadenopathy is the most common lesion presenting as a mass in the middle compartment of the mediastinum .

The most common causes include:

- Lymphoma.
- sarcoid.
- metastatic lung cancer.

## 2. Cysts

*\*Cystic masses comprise approximately 20 percent of middle mediastinal masses.\**

These cysts could be:

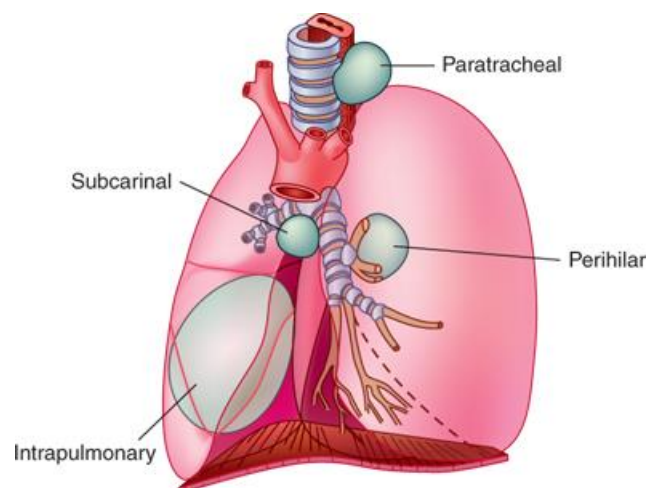
1- **Pericardial cysts.** rare

2- **Esophageal Duplication Cyst:**

- They are a congenital malformation of the posterior primitive foregut.
- Adjacent to or embedded in wall of esophagus
- Can have respiratory or GI epithelium
- May either obstruct or erode through esophageal wall
- Other GI related duplication may also be seen: Thoraco-abdominal duplications that originate near duodenum & jejunum and expand to middle mediastinum (gastric mucosa & vertebral anomalies).

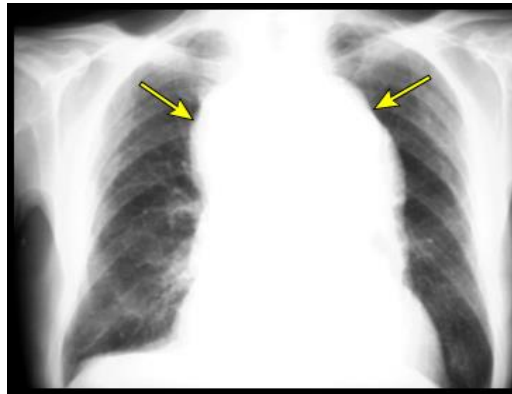
3- **Bronchogenic cysts:**

- Secondary to abnormal lung budding during development.
- Can be adjacent to or far away from bronchogenic structures.
- Usually have respiratory epithelium.
- Bronchogenic cysts are the most common cystic lesions.
- Bronchogenic cysts are more common in men.
- These lesions are sometimes identified because patients have symptoms of substernal pain, cough, **recurrent infection symptoms**, or dyspnea. Nowadays, many cases are diagnosed antenatally.
- They are typically located in the right paratracheal region and in the subcarinal location.



### 3. Cardiovascular aneurysm or anomaly

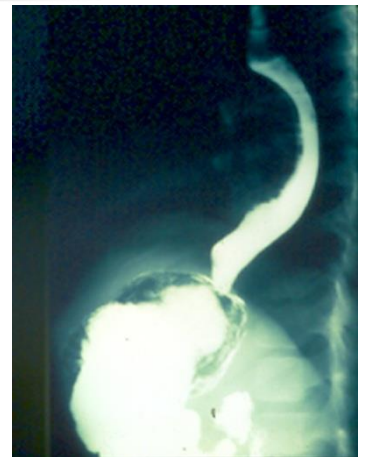A variety of cardiovascular pathologies (eg, thoracic aortic aneurysm, pulmonary artery aneurysm, vascular rings) can present as a mediastinal abnormality.



### 4. Esophageal tumors

Advanced esophageal tumors may be identified on imaging as a mediastinal mass; however, the location and symptoms such as dysphagia, weight loss, and occult blood loss are not likely to be confused with lymphadenopathy or other middle mediastinal masses.

Contrast esophagegogram is used to identify the tumor.



## \*Posterior mediastinal masses\*

### Neurogenic tumors

Neurogenic tumors represent more than 60 percent of posterior mediastinal masses. These lesions are classified based upon their **neural cell of origin**.

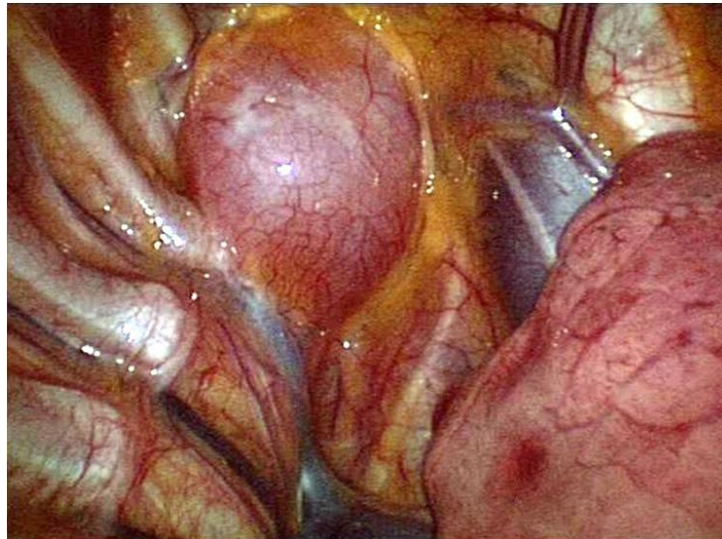
- 1- **Schwannomas and neurofibromas** are benign lesions that arise from the intercostal nerve sheath and make up **90 percent** of adult neurogenic tumors.



**2- Neuroblastomas and ganglioneuroblastomas:**

- Are malignant tumors that occur most commonly in children and originate from the sympathetic ganglia.
- Very good prognosis, especially Stage I & II
- Paraplegia implies compression of spinal cord ( do MRI & urgent laminectomy)

**3- Ganglioneuromas** are benign lesions that arise from the sympathetic ganglia and are most common in young adults.



# Cardiac surgery

- Introduction: page 37
  - Written by: Hashim Ahmad
- Cardiopulmonary bypass: page 46
  - Written by: Majd Al Rawashdeh
  - Corrected by: Hashim Ahmad
- Coronary Artery Disease: page 51
  - Written by: Malak Al-Kasasbeh
  - Corrected by: Hashim Ahmad
- Valvular diseases: page 61
  - Written by: Ayat M. Zghoul
- Prosthetic heart valves: page 76
  - Written by: Ayat M. Zghoul
- Congenital heart diseases: page 80
  - Written by: Mohammad Qussay Al-Sabbagh

# Anatomy of the Heart

Note: To make it as brief as possible, anatomic figures were omitted from this quick revision. Please refer to an anatomy atlas for further understanding of anatomical descriptions.

## General Features

- The heart is a hollow muscular organ located in the **middle mediastinum** within the pericardial sac. It **rests on the central tendon of the diaphragm** and is flanked on either side by the right and left pulmonary cavities.
- The **apex**, located approximately at the **5th intercostal space**, projects anteriorly, inferiorly, and to the left and moves freely within the pericardial sac.

## Surfaces and Borders of the Heart:

### Surfaces:

- The anterior (costosternal) surface is formed mainly by the RV.
- The base on the posterior and superior sides of the heart is formed mainly by the LA and is in close proximity to the esophagus.
- The diaphragmatic surface on the inferior side of the heart, formed by the left and right ventricles.

### Borders:

- The right border is formed by the right atrium.
- The left border is formed by the LA and LV.
- The apex is formed by the LV.

The borders of the heart define the cardiac shadow that is seen on radiographic images

## The Wall of the Heart:

- The wall of the heart consists of three layers: **the epicardium** (formed by the visceral layer of the serous pericardium), **the myocardium**, and **the endocardium**.
- The **myocardium** is the **thick** layer, being thickest in the walls of the ventricles.
- The endocardium lines the inner aspect of the chambers and valves of the heart. Being the farthest from blood supply, it is the first part of the cardiac wall to be affected by ischemia.

## Cardiac Skeleton:

A cardiac skeleton of dense fibrous connective tissue forms four fibrous anuli (rings) and intervening trigones that separate the chambers of the heart, provide anchoring points for cardiac muscle fibers and cardiac valves, and insulate electrical impulses of the heart's conduction system.

## Chambers of the Heart:

### Atria:

- The atria are the **thin-walled inflow chambers** of the heart. The RA receives the SVC and IVC from the systemic circulation and the cardiac veins from the heart. The left atrium receives the pulmonary veins from the lungs.
- RA: the right atrium has two parts:
  - a) Anterior muscular part (atrium proper): this is the part that contracts at the end of ventricular filling during diastole.
  - b) Posterior smooth part (venous sinus: contains the openings of the SVC, IVC, and cardiac veins.
- LA: Smaller but thicker walled than the right atrium. Its walls are smooth except in the auricle.

### Ventricles:

The ventricles are thick-walled chambers that connect to the out-flow channels (the pulmonary artery and the aorta).

- The muscular wall of the ventricles is made of meshwork of thick muscular ridges known as **trabeculae carnae**.
- **The interventricular septum:** most of it is muscular, but there is a small membranous part at the superior end that is a common site of septal defects (VSD).
- **Each ventricle has two parts:** the ventricle proper (the inflow portion that receives blood from the atria), and an outflow portion that sends blood to the aorta and pulmonary trunk (infundibulum in the RV and aortic vestibule in the LV).
- Papillary muscles arise from the walls of the ventricles or the interventricular septum and are attached to the cusps of the AV valves by chordae tendineae.
- After MI, these muscles may be deprived of blood causing their rupture with subsequent mitral regurgitation.

## Conduction System of the Heart

The conduction system of the heart generates and transmits impulses that modulate the contraction of the cardiac muscle.

- The sinoatrial (SA) node, the native pacemaker of the heart, initiates and the electrical impulse and coordinates the timing of the contraction of the heart. It is located at the junction of RA and SVC and contains specialized myocytes that have the ability to depolarize spontaneously (automaticity) at a regular rate of 60–100 beats per minute at rest.
- Each part of the heart, including the myocardium, is capable of initiating impulses but the at a slower rate than the SA node.
- Branch to the SA and AV nodes arise from the right coronary artery, and that is why inferior wall MI (which is caused by occlusion of the RCA causes bradycardia or AV block).
- The atrioventricular (AV) node is stimulated by the SA node and transmits impulses to the AV bundle. It is subendocardial, located in the posteroinferior part of the interatrial septum near the coronary sinus.
- His bundle arises from cells of the AV node and runs along the membranous part of the interventricular septum.

### Atrioventricular heart block

Atrioventricular (AV) heart block is a partial or complete blockage of the conduction of electrical impulses between the atria and ventricles. This causes **bradycardia** and **arrhythmias** and **syncope** when CO is significantly decreased to cause cerebral hypoperfusion. This most commonly occurs after MI.

## Pericardium

The pericardium is composed of two layers: the outer fibrous pericardium and the inner serous pericardium. It covers the heart and proximal portion of the great vessels.

- 1- Fibrous pericardium is the tough connective tissue that tethers the heart in place via its connections to the sternum anteriorly, the central tendon of the diaphragm inferiorly, and the tunica adventitia of the great vessels superiorly.
- 2- Serous pericardium comprises two layers: the parietal layer and the visceral layer.

- a) The parietal layer is continuous with the internal aspect of the fibrous pericardium.
- b) The visceral layer, also known as the epicardium, is the thin innermost layer of the pericardium. This layer contains the major branches of the coronary arteries.

### Blood supply and Innervation:

- Pericardiophrenic arteries, branches of the internal thoracic arteries, provide the main blood supply to the pericardium. Veins that accompany the arteries drain into the superior vena cava.
- Fibrous pericardium and the parietal layer of serous pericardium are supplied by phrenic nerves. The visceral layer is innervated by branches of sympathetic trunks and vagus nerves.
- Pericardial pain is often referred via the phrenic nerve to the skin of the ipsilateral supraclavicular region (dermatomes C3–C5). Hence, pain of pericarditis can be referred to the shoulder.

### Pericarditis

Pericarditis is an inflammation of the pericardium, which causes sharp, retrosternal or epigastric pain and a characteristic pericardial friction rub on auscultation. Pericarditis can lead to pericardial effusion or cardiac tamponade and may be accompanied by dyspnea and peripheral edema.

### The Pericardial Cavity

The pericardial cavity is the space within the pericardial sac between the parietal and visceral layers of the serous pericardium.

- The pericardial cavity is filled with a thin layer of serous fluid (15-50 mL of plasma ultrafiltrate) that allows for **frictionless movement of the heart**.
- Two pericardial recesses form where the serous pericardium reflects around the roots of the great vessels:
  1. **The transverse pericardial sinus** is a passage between the inflow channels

### Surgical significance of the transverse pericardial sinus

During cardiac surgery, the surgeon is able to isolate (and clamp) the heart's outflow tracts, the aorta and pulmonary trunk, from its inflow tracts, the superior vena cava and pulmonary veins, by passing the clamps through the transverse pericardial sinus.

(superior vena cava and pulmonary veins) and the outflow channels (aorta and pulmonary trunk) of the heart.

2. **The oblique pericardial sinus** is a recess of the pericardial cavity posterior to the heart between the right and left pulmonary veins.

---

## Blood Supply of the Heart

The arterial supply of the heart is provided by the right and left coronary arteries which arise from the ascending aorta immediately distal to the aortic valve. These arteries and their branches are distributed over the surface of the heart.

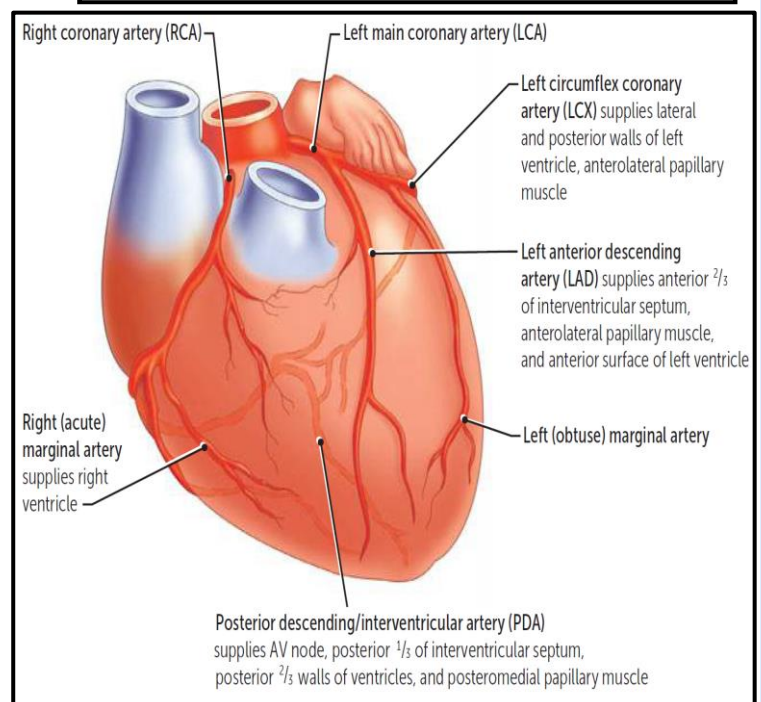
- The right coronary artery:
  - It Arises from the anterior aortic sinus of the ascending aorta and runs in the right AV groove
  - It gives branches to the right atrium and the SA node.
  - It gives ventricular branches to the right ventricle; the marginal branch is the most important one.
  - If dominant, it continues as the posterior interventricular (descending) artery.

- The Left main coronary artery:
  - Arises from the left posterior aortic sinus of the ascending aorta.
  - This artery is short.
  - It gives the anterior interventricular branch (AKA left anterior descending artery

### Dominant Circulation

The coronary artery that gives the posterior descending artery (PDA) that meets the LAD at the apex is considered the dominant artery of the heart.

- Right-dominant circulation = 85% (PDA arises from RCA.)
- Left-dominant circulation = 8% (PDA arises from left circumflex coronary artery [LCX].)
- Co-dominant circulation = 7% (PDA arises from RCA and LCX.)





(LAD) or the widow artery), which runs in the anterior interventricular groove reaching the apex. It gives septal branches to the interventricular septum and diagonal arteries to the left ventricle.

- Also, it gives the left circumflex artery which runs in the left atrioventricular groove and gives 2 branches (obtuse and marginal).

## Embryology of the Heart

### Embryonic Heart Structures and Adult Derivatives

By the third week of development, the rapidly growing embryo can no longer rely on simple diffusion from the placenta for its metabolic and oxygen requirements. It is no surprise, then, that the heart is the first functioning organ in vertebrate embryos, and a primitive heart begins to beat by **week 4 of development**. For understanding the detailed process of heart development, it is better to read Dr. Faraj lectures in the basics of heart embryology which is beyond the scope of this dossier. A summary of embryonic structures and their adult derivatives is shown in the table below.

#### In A Nutshell

The heart is first functional organ in vertebrate embryos; beats spontaneously by week 4 of development.

Embryonic Structure	Adult Structure
Truncus arteriosus	Ascending aorta and pulmonary trunk
Bulbus cordis	Smooth parts (outflow tract) of left and right ventricles
Primitive ventricle	Trabeculated parts of left and right ventricles
Primitive atrium	Trabeculated parts of left and right atria
Left horn of sinus venosus (SV)	Coronary sinus (largest venous drainage of heart)
Right horn of SV	Smooth part of right atrium
Right common cardinal vein and right anterior cardinal vein	Superior vena cava
Vitelline veins	Portal system

### Development and Looping of Heart Tube

A primitive heart tube develops from **mesodermal cells** at the cranial end of the embryo during gastrulation. The steps of looping are as follows:

1. Primitive heart chambers lined with endothelial cells form along the cranial-caudal axis of the heart tube.

2. Rapid elongation of the heart tube occurs in a confined space (the pericardial cavity), requiring that it bend into a U-shaped loop that places the primitive atrium behind the more-prominent primitive ventricle. Note that in the early stages, the primitive atrium is connected to the ventricle via a common atrioventricular (AV) canal.

### **Dextrocardia**

Defects in dynein (protein in cilia involved in L/R asymmetry) or cardiac looping can lead to dextrocardia, a condition in which the heart lies on the right side of the thorax. It often accompanies Kartagener syndrome, an autosomal recessive genetic disorder that results in dysfunctional cilia in the reproductive and genitourinary tracts as well.

### **Formation of Septa**

Heart septa divide the atrioventricular canal, atrium, ventricle, and aortocapulmonary (ventricular outflow) tract into discrete chambers. Septa form between the fourth and sixth weeks of development from inward growth of the innermost (endocardial) cardiac surface. Although all septation events occur simultaneously, for clarity, these steps are detailed individually for each structure below.

#### **Atrioventricular Canal Septum**

The common AV canal is split into two canals by endocardial cushions, which are endocardial inward growths that fuse together from the anterior and posterior canal walls. Abnormal fusion of endocardial cushions can lead to endocardial cushion defects, which are a broad class of congenital heart defects with abnormal septation of the atria, ventricle, and/or AV canal.

**Atrial Septum** (explained later in the text).

#### **Interventricular Septum**

The interventricular septum consists of two parts: the muscular portion and the membranous portion.

- The muscular interventricular septum forms as an upward expansion of the base of the primitive ventricle. It extends toward the AV septum but does not reach it; the resulting gap is the interventricular foramen.
- The membranous interventricular septum is created by the fusion of the aortocapulmonary septum with the muscular intraventricular septum. It

grows downward from the AV cushions and fuses with the muscular interventricular septum, obliterating the interventricular foramen.

- Ventricular septal defect (VSD), an abnormal opening in the interventricular septum, is the most common congenital heart malformation (Figure 1-3). The most common location is in the membranous interventricular septum, resulting from incomplete fusion of the AV cushions with aorticopulmonary septum. Clinical manifestations of a VSD vary depending on the size of the defect. Fifty percent of small VSDs undergo complete or sufficient partial closure by age 2 and do not require intervention. Larger VSDs result in left-to-right shunting of blood, and, as a result, may present with late cyanosis.
  - A classic symptom is easy fatigability.
  - Cardiac auscultation reveals a harsh holosystolic murmur heard best at the left lower sternal border.

### Aorticopulmonary Septum

The aorticopulmonary (AP) septum is derived from **neural crest cells** that migrate into the primitive ventricular outflow tract. It is responsible for **separating the truncus arteriosus into the aorta and pulmonary artery**. As the septum descends, it spirals 180 degrees so that the aorta becomes the left ventricular outflow tract and the pulmonary trunk becomes the right ventricular outflow tract. **Failure of spiraling** leads to congenital malformations that involve right-to-left shunting and early cyanosis in the newborn period.

- **Persistent truncus arteriosus** results from abnormal migration of neural crest cells and subsequent failure of formation of the AP septum. Therefore, separation of the left ventricular and right ventricular outflow tracts never occurs. The aorta and pulmonary trunk form a common tract leaving the ventricles, which allows mixing of oxygenated and deoxygenated blood.
- **Transposition of the great vessels** occurs when the AP septum **fails to spiral 180 degrees**. The left ventricle (LV) is connected to the pulmonary trunk, and the right ventricle (RV) is connected to the aorta (Figure 1-4). This condition results in a complete right-to-left shunt and early cyanosis.
- **Tetralogy of Fallot** is caused by anterior displacement of the AP septum. The four abnormalities are **overriding aorta, pulmonic stenosis, RV hypertrophy, and VSD**. The primary defect is termed an “**overriding aorta**,” because the misplaced aorta partially obstructs the right ventricular outflow tract, leading to right ventricular outflow obstruction

(pulmonic stenosis). Pulmonic stenosis leads to increased pressures in the RV and subsequent right ventricular hypertrophy. The membranous VSD results from a failure of fusion between the AP septum and the muscular portion of the intraventricular septum (IVS). **Right-to-left shunting results in early cyanosis.**

# Cardiopulmonary bypass (CPB)

## Background

- Cardiac surgery means that you will stop the pumping action of the heart for a period of time. If the circulation is temporarily stopped **at normal body temperature**, organs suffer ischemic damage owing to lack of oxygen, the extent varying according to the metabolic demand of the organ. **The brain** is the most sensitive tissue in this respect and is liable to irreversible changes after 4 min of ischemia. The spinal cord is next, followed by heart muscle, which will tolerate about 10 min of ischemia at normal temperature. The tolerance to ischemia can be increased slightly by **lowering the metabolic rate by hypothermia**.
- Prior to the development of cardiopulmonary bypass, surgery on the heart was limited to procedures that could be performed rapidly on a beating heart, such as mitral valvotomy to relieve mitral stenosis, where a finger is passed blindly through the left atrial appendage and through the stenotic mitral valve. Another alternative was to cool the patient, when periods of up to 10 min permitted very simple procedures to be performed safely, such as closure of an atrial septal defect (ASD).
- **Following the development of cardiopulmonary bypass**, it is now possible to stop the heart for prolonged periods while a machine is used to take over the pumping and oxygenation of the blood. Generally, a combination of **hypothermia and cardiopulmonary bypass** is used.
- Cardiopulmonary bypass (CPB) was first used successfully in **1953** by John Gibbon and has since revolutionized cardiac surgery

## Definition

A Pump and oxygenation apparatus that temporarily takes the blood **from the SVC and IVC** and returns it **to the aorta**, bypassing the heart and lungs and **allowing cardiac arrest** or open-heart procedures, heart transplant, lung

### Surgical Approach to the Heart:

- 1- **By a median sternotomy:**  
An incision is made from the suprasternal notch to the lower end of the xiphisternum. The sternum is divided and retracted to expose the thymus superiorly and the pericardium inferiorly. The thymus and pleurae are dissected from the pericardium, and the pericardium is opened.
- 2- **By left anterolateral thoracotomy.**

transplant, or heart-lung transplant as well as procedures on the proximal great vessels in the presence of a still bloodless heart.

## INITIATING CPB

### The general technique of cardiopulmonary bypass (CPB)

- 1- Before cannulation for CPB, the patient is fully heparinized to prevent clotting of blood inside the machine.
- 2- After full heparinization, **cannulas are inserted into the SVC and IVC** via the right atrium to siphon off the venous return from the systemic circulation.
- 3- The blood is then pumped through an oxygenator and a heat exchanger before returning to the systemic circulation via a **cannula in the ascending aorta or femoral artery**.

This form of bypass will perfuse the whole body with oxygenated blood at an adequate pressure while diverting it from the heart and lungs. The heart may now be stopped and cooled by infusion via the coronary arteries of **cold 'cardioplegic' solution containing potassium** to produce rapid cardiac arrest in diastole. With **the aorta is cross-clamped**, the heart may be opened in a bloodless field with access to all chambers.

### Arterial and Venous Cannulation

- **Arterial cannulation**
  - The great vessels are exposed and an aortic perfusion cannula is inserted into the **ascending aorta**, held in place by the purse-string suture. Air is excluded and the cannula connected to the bypass circuit.
  - Alternative cannulation sites include: the femoral artery or the axillary artery. These are used when there is a condition that prevents cannulation of the aorta (aortic dissection, in aortic root surgery ... etc.).

- **Venous cannulation**

A single 'two-stage' venous cannula placed in the right atrium establishes venous drainage. The venous pipe has end holes that sit in the inferior vena cava and side holes that sit in the right atrium (to take the drainage from the superior vena cava).

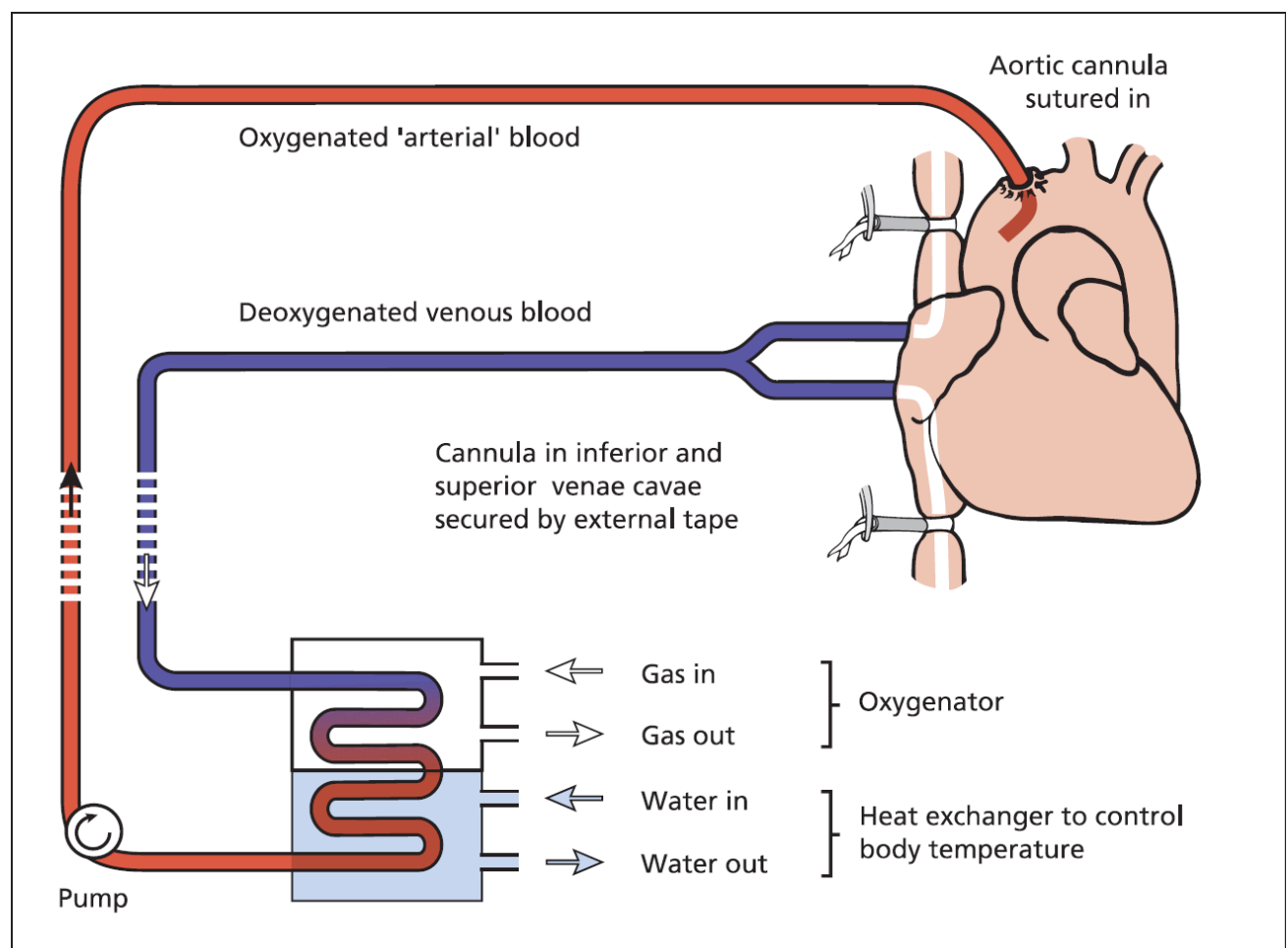
Alternatively, the superior and inferior vena cavae may be cannulated **separately** to gain better control over the venous return and to facilitate surgery within the right atrium

- **Cardiopulmonary bypass circuit**

Once the circuit is connected, the CPB machine (the 'pump') gradually takes over the processes of **circulation** and **ventilation**.

To bypass the heart and lungs, blood is pumped from a venous reservoir and oxygenated using an **oxygenator** that allows gas exchange across its membrane.

- To further increase the efficiency of the process, CPB is combined with **hypothermia** to decrease the metabolic demands of the tissues. This can be achieved by lowering the core systemic temperature by passing the returning blood through a **heat exchanger**.
- The blood is also filtered to remove particulate emboli and returned to the systemic arterial circulation via a pump.





## Myocardial Protection

- Once CPB has been established, the ascending aorta is usually cross-clamped to obtain a bloodless operative field. The heart ceases to eject and becomes anoxic due to inhibition of coronary blood flow. Permanent myocardial damage can develop within 15–20 minutes, therefore most cardiac operations require some form of myocardial protection.
- The methods of myocardial protection include **intracoronary infusion of a cardioplegic solution**, **intermittent cross-clamp fibrillation** and **total circulatory arrest**.

### Myocardial Protection Methods:

#### 1- Cardioplegic solutions:

- Most cardioplegic solutions contain **potassium** as the arresting agent. Potassium arrests the heart in diastole by depolarization of the membrane.
  - **Cold** (4–10°C) isotonic crystalloid or blood solutions aid myocardial protection by reducing metabolic requirements through local hypothermia.
  - **Warm** cardioplegic solutions, on the other hand, may facilitate better myocardial repair recovery postoperatively by aiding intramyocardial enzyme activation.
- 2- **Intermittent cross-clamp fibrillation.**
- 3- **Total circulatory arrest .**

### Anticoagulation during the procedure:

- Anticoagulation is necessary just before and during the procedure, with **heparin**.
- ✓ Coagulation can occur due to blood exposure to the non-physiological surface of the CPB circuit.
- ✓ At the end of the procedure, anticoagulation is reversed by **protamine**.
- ✓ **Heparin rebound**: Increased **anticoagulation** after CPB from **increased heparin levels**, as increase in peripheral blood flow after CPB returns heparin residual that was in the peripheral tissues.

## Complications

- **Emboli**
  - 1- **Air emboli:** air may be entrapped during formation of the bypass circuit or entering during bypass.
  - 2- **Thromboembolism:** thrombus may be formed in the bypass circuit, and may embolize into the cerebral circulation causing stroke, or to any other site.
- **Postoperative hemorrhage**
  - This may result in **cardiac tamponade**.
  - Passage through the bypass circuit activates the clotting cascade and **consumes platelets**, thus increasing the risk of hemorrhage.
- Trauma to formed blood elements (especially thrombocytopenia and platelet dysfunction)
- Pancreatitis (low flow)
- Heparin rebound
- CVA
- Failure to wean from bypass
- Technical complications (operative technique)
- MI

## Notes

- **Cardiac tamponade & pneumothorax** are the two mechanical problems that can decrease CO after CPB.
- To manipulate cardiac output after CPB you can manipulate **the Rate, rhythm, afterload, preload, inotropes & mechanical manipulation**.

# Coronary Artery Disease



## INTRODUCTION

### Definition:

- Myocardial ischemia occurs when there is **imbalance** between the oxygen supply and demand of the heart. This can be due to:
  - **Decreased blood flow** due to coronary artery disease (CAD).
  - **Decreased flow of oxygenated blood:** Anemia, carboxyhemoglobinemia, and hypotension.
  - **Increased demands:** this can be due to increase in cardiac output (e.g. thyrotoxicosis) or myocardial hypertrophy (e.g. from aortic stenosis, or hypertension).
- The most common cause of ischemic heart disease (IHD) is coronary artery disease (CAD).
- Coronary artery disease can be due to: atherosclerosis, thrombosis, spasm, embolus, and coronary arteritis (e.g. in SLE).
- In normal situations, cardiac cells extract almost all the oxygen they get (high extraction ration). When oxygen demand of the heart increases, blood flow increases by vasodilation not by increasing the degree of oxygen extraction.
- Critical stenosis of the coronary artery (> 70% occlusion) will lead to significant reduction of blood flow. CAD gives rise to a wide range of clinical presentations, ranging from relatively stable angina through to the acute coronary syndromes (including unstable angina and MI).

### Epidemiology:

Coronary artery disease is the most common cause of death in the developed countries. It is more prevalent in men than in women although incidence in women is rapidly increasing.

## ? ETIOLOGY

- 1- **Atherosclerosis** (>90% of cases):
  - Atherosclerosis is a chronic systemic inflammatory process. It affects the branches of the aorta, coronary, renal, peripheral and sometimes mesenteric arteries. Symptoms of atherosclerosis are related to the site of the lesion.
  - Atherosclerosis occurs when damage to the endothelium allows plasma lipoproteins to leak into the intima. Lipids are oxidized then consumed by macrophages resulting in foam cells appearance. Inflammation and healing results in deposition of ECM and proliferation of smooth muscles. Different histopathological stages of atherosclerosis have distinct features:
    - a) Begin as fatty streaks, which are flat yellow lesions in the intima. These consist of smooth muscle cells, which are filled with cholesterol, and foam cells. These fatty streaks appear early in life (10-14 years of age) as the first evidence of atherosclerosis.
    - b) Continue as fibrous plaques which consist of smooth muscle cells, foam cells and leukocytes. As plaques grow, they project into the lumens of blood vessels causing stenosis and ischemia. Any stenosis in an artery of >70% of the diameter (90% reduction on cross-sectional area) is considered critical.
    - c) Complicated lesions occur when plaques rupture leading to exposure of sub-endothelial collagen and activation of Von Willebrand factor → activation of the coagulation cascade → platelets aggregation and thrombosis. This leads to complete occlusion of the vessel and the patient develops an acute coronary syndrome or acute MI.
- 2- **Embolization**: emboli most commonly originate from the left atrium.
- 3- **Coronary spasm**: due to sudden exposure to cold, even without any previous stenosis.
- 4- **Vasculitis**: inflammation affecting medium sized arteries, such as; Behcet's disease & Takayasu disease.
- 5- **Severe left ventricular hypertrophy**: causing compression on the coronaries.
- 6- **Congenital anomalies of the coronary arteries**: left circumflex artery emerging from the right coronary artery, LAD emerging from the right main coronary, right main coronary emerging from the right posterior aortic sinus so that it is compressed between the aorta and the pulmonary artery, and anomalous origin of LAD artery from pulmonary artery

## Risk factors:

Modifiable	Non-modifiable:
<ul style="list-style-type: none"><li>- HTN</li><li>- DM</li><li>- Hyperlipidemia/ hypercholesterolemia</li><li>- Smoking</li><li>- Obesity</li><li>- Reduced physical activity</li></ul>	<ul style="list-style-type: none"><li>- Advancing age</li><li>- Male gender (only before 55, then both males and females are at the same risk).</li><li>- Race</li><li>- Family history</li></ul>



## CLINICAL FEATURES

### Signs and symptoms:

- Chest pain
  - Angina (pain lasts for less than 60 mins):

Angina is classified into stable and unstable angina. Any new-onset angina, angina occurring at a higher frequency, angina occurring with minimal activity (sometimes at rest), or becoming unresponsive to nitrates is considered unstable.
  - Myocardial infarction (pain lasts for more than 60 mins)
- Breathlessness
- Fatigue
- Swelling (lower limb edema, ascites, pulmonary edema...)
- Palpitations
- Syncope
- Sudden death

#### Canadian cardiovascular society classification of angina:

- I: No angina with ordinary physical activity
- II: Slight limitation of ordinary activity
- III: Marked limitation of ordinary activity
- IV: Symptoms with any activity or at rest

## Complications:

Mechanical complications of MI are rare with early revascularization, however, MI causes myocytes necrosis which heals to form scar tissue.

- Full thickness necrosis of ventricular wall:
  - Free rupture of the ventricle: this is fatal without treatment.
  - Interventricular septal rupture (post-infarction VSD): this presents 3-7 days after infarction as pulmonary edema, pansystolic murmur and hypotension. Diagnosis is done by echocardiography and is treated by pericardial/ artificial Dacron patch.
  - Papillary muscle necrosis (mitral regurgitation): this is a very common complication that presents as pansystolic murmur with pulmonary edema. It is diagnosed by echocardiography and right heart catheterization and treated by mitral valve replacement.
- Partial thickness necrosis of ventricular wall:
  - Ventricular aneurysm: free wall is replaced with non-contractile fibrous tissue that balloons out during systole → ↓ stroke volume. This is treated by cardiopulmonary bypass and CABG with valve replacement if necessary (combined procedure).



## DIAGNOSIS

### History taking and physical findings:

- Severity of symptoms and the extent to which the symptoms interfere with everyday activities form a significant part of the clinical history, an assessment of risk factors should also be included.
- Physical examination is often normal, however, any evidence of myocardial ischemia or stigmata of associated disease, such as diabetes or peripheral arterial disease, should be noted.

### Investigations:

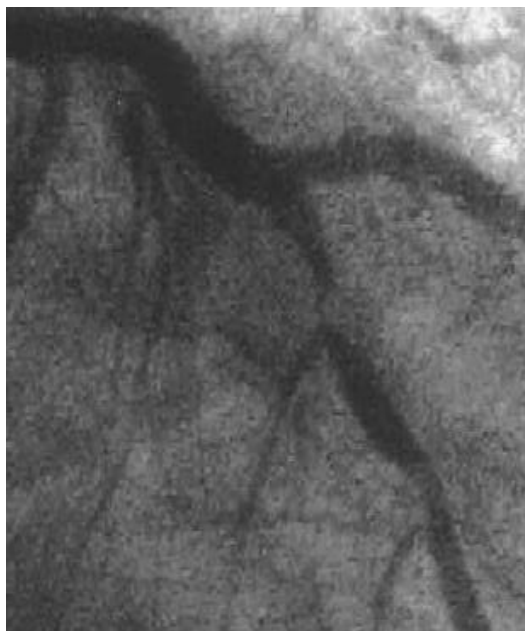- **Non-invasive methods of diagnosis:**
  - Resting ECG
  - Troponin and cardiac isoenzymes

- Chest x-ray
- Fasting blood sugar (FBS)/ HbA1c
- Serum lipids
- Treadmill test (TMT)
- Physical stress test or pharmacologic stress myocardial perfusion studies (PET scan & radionuclide studies)
- Echocardiography
- Cardiac MRI
- Cardiac CT scan has become a screening test for the presence of any calcified lesions. 3D reconstruction can also be done after controlling the heart rate around 60 and giving  $\beta$  blockers.

- **Invasive methods of diagnosis:**

- 1- Coronary angiography:

- Remains the 'gold standard' diagnostic technique.
- Contrast is injected into coronary vessels to visualize any stenotic lesions. Location and size of the lesions can be detected.
- Ventricular function can be assessed.



This is a photo with 90% stenosis in the artery. In other cases, it might be hard to accurately estimate the degree of stenosis, so we use more advanced techniques:

- a) Endovascular ultrasonography: by inserting a catheter inside the coronary artery.
- b) Fractional flow reserve (FFR): by inserting a catheter distal to the narrowing and measuring the impedance of the flow.





## TREATMENT

- Nitrates and vasodilators.
- Dual anti-platelet therapy:
  - Aspirin (Acetylsalicylic acid): works by inhibiting COX enzyme, which is responsible of thromboxane A<sub>2</sub> synthesis.
  - Clopidogrel (Plavix): works by blocking ADP receptors on platelets.
  - GPIIa/IIIb receptor antagonists (Abciximab) are potent drugs used in acute cases.
- Beta blockers: they decrease the stress on myocardial cells by decreasing the contractility of the heart and the demand of oxygen.
  - They might be given in heart failure in small doses to up-regulate beta receptors found in the heart.
- Calcium channel blockers: essential in coronary spasm.
- Lipid lowering agents (Atorvastatin 20 mg in people with a 10-year risk of cardiovascular disease  $\geq 10$ )
- Controlling HTN & DM.
- **Revascularization.**
  - 1- Catheter based coronary interventions/ percutaneous coronary interventions (PCI):
    - Balloon angiography: balloon dilation to remove the obstruction, stenosis often recurs.
    - Coronary stenting: stents are placed to prevent restenosis. Stents can be “bare metal stents” or “drug eluting stents (e.g., sirolimus)”. New stents are “bioreabsorbable” which will be enzymatically degraded.
  - 2- Surgical revascularization (coronary artery bypass surgery (CABG)):
    - Construction of bypass grafts to downstream segments of the affected coronary arteries to re-establish normal blood flow to the myocardium.

### Indications of coronary artery bypass surgery (CABG):

- 1- Triple vessel disease:
  - Especially in diabetic patients and patients with low ejection fraction.

- 2- Critical left main stem disease
- 3- Stenosis proximally in the LAD
  - In the last 10 years, catheterization has improved and many patients, who had stenosis in the LAD and refused to undergo CABG, underwent LAD catheterization and stenting. This could be done in specific circumstances and after scoring patients via SYNTAX score 2 to decide whether balloon stenting could be done to them or not. However, CABG is still the gold standard for LAD stenosis.
- 4- Unstable angina refractory to medical treatment
- 5- Failed percutaneous intervention
  - Complications such as; ECG changes or cardiac arrest, could occur during PCI due to rupture, dissection or thrombosis of the artery. These patients should undergo surgery immediately, with a higher mortality rate than those who undergo selective CABG.
- 6- Life threatening complications of MI
- 7- Anomalies in the coronary artery

### Selection of conduit:

Venous grafts	Arterial grafts
<ul style="list-style-type: none"> <li>- The most common vein conduit is the <u>long saphenous vein</u> because it is straight forward to harvest, it provides good length and is easy to handle.</li> <li>- Its 10-year patency rate is reported to be 50% (less than arterial grafts due to more</li> </ul>	<ul style="list-style-type: none"> <li>- <u>Left internal mammary artery (LIMA)/ left internal thoracic artery</u> is the conduit of choice for the LAD with 10 years patency rates &gt;90% due to less fenestrations in the endothelium than venous conduits and less intermolecular junction permeability with higher heparin sulfate and NO production.</li> </ul>

<p>fenestrations in the endothelium and higher intermolecular junction permeability, fewer heparin sulfate and fewer NO production).</p> <ul style="list-style-type: none"> <li>- Grafts are constructed from the ascending aorta to the target vessel and when stenosis recurs we re-intervene percutaneously or surgically.</li> <li>- Alternative venous conduits: <ul style="list-style-type: none"> <li>• Short saphenous</li> <li>• UL veins (e.g., cephalic vein)</li> </ul> </li> </ul>	<p>Complications of venous grafts (such as atherosclerosis) are also avoided because the diameter &amp; the thickness of the wall of an arterial conduit are more suitable than those of a venous conduit.</p> <ul style="list-style-type: none"> <li>- <u>Bilateral internal mammary artery grafts (BIMG)</u> are also used</li> <li>- <u>Radial artery</u>: Although it is more prone to spasm than other arterial conduits, it is used for right main coronary, to follow the concept of total arterial revascularization; to improve long term results of coronary surgery.</li> <li>- Alternative arterial bypass grafts include: <ul style="list-style-type: none"> <li>• Gastroepiploic artery</li> <li>• Inferior epigastric artery.</li> </ul> </li> </ul>
---	---

### The operation:

- The chest is opened via a **median sternotomy** and LIMA is dissected from the chest wall.
- The patient is typically placed in CPB after heparinizing.
- The aorta is cross-clamped and the heart is arrested via a cardioplegic solution which is rich in K<sup>+</sup>.
- The grafts are anastomosed to coronary arteries distal to the site of stenosis which was previously determined by coronary angiography. It can be determined by palpating the vessel during surgery.

- The aortic cross-clamp is removed and the heart is re-perfused with oxygenated blood
- A side-biting clamp is applied to the ascending aorta and the proximal anastomoses are completed, however, the surgeon may opt to carry out the whole operation while the cross-clamp is applied to reduce the risks associated with aortic manipulations.
- The patient is warmed and weaned from CPB.
- Heparin is reversed and the patient is returned to the ICU
- Discharge is routinely 4-8 days after surgery.

### **Postoperative complications:**

- Bleeding:
  - 2-3% of the patients
  - Rarely, acute cardiac tamponade or profound hypotension may occur in the early postoperative period and requires emergency re-sternotomy.
- Arrhythmias:
  - The most common arrhythmia in patients undergoing CABG is sinus tachycardia, closely followed by atrial fibrillation. Atrial fibrillation often spontaneously reverts to NSR. If not, we treat it.
- Poor cardiac output state: this may be due to reperfusion-type injury.
  - Postoperative pharmacological support: Inotropic agents with vasodilators and lipid lowering agents (mentioned above in the treatment section)
  - Postoperative mechanical support (for further details, read Baily and Love's page 830).
- Neurological dysfunction: Stroke leading to focal neurological deficit occurs in approximately 2 % of patients following CABG. This might be due to embolization from the aortic arch or heart chamber or hypoperfusion causing watershed areas infarcts.
- Wound infection
- Mortality: Occurs in 2-3% of patients following CABG.

### **Surgical outcome:**

- Relief of symptoms: 90% at 1 year, 80% at 5 years, 60% at 10 years.
- Survival rates: 95% at 1 year, 90% at 5 years, 75% at 10 years.

**Minimal access surgery (Minimally invasive heart surgery (MIHS)/ Minimally invasive direct coronary artery bypass (MIDCAB) grafting):**

- Also called (keyhole surgery)
- Performed through a strategically placed minimal access incision and so avoids all invasive aspects of conventional CABG.
- Through an anterior sub-mammary incision, the LIMA can be dissected down with the aid of a thoracoscope and grafted to the LAD.
- More lateral MIDCAB incisions allow access to other coronary vessels including branches of the circumflex artery.
- So, MIDCAB grafting achieves all the desired results of conventional heart surgery, but with:
  - 1- Minimal harm to the patient (less trauma & less pain).
  - 2- Smaller incisions, sited in the least visible locations.
  - 3- Make the scars most cosmetic.
  - 4- Without the use of harmful surgical equipment.
  - 5- Less risk of infection.
  - 6- Less bleeding.
  - 7- Decreased length of stay in hospital (2-5 days Vs 7-10 days).
  - 8- Decreased recovery time (1-4 weeks Vs 6-8 weeks).

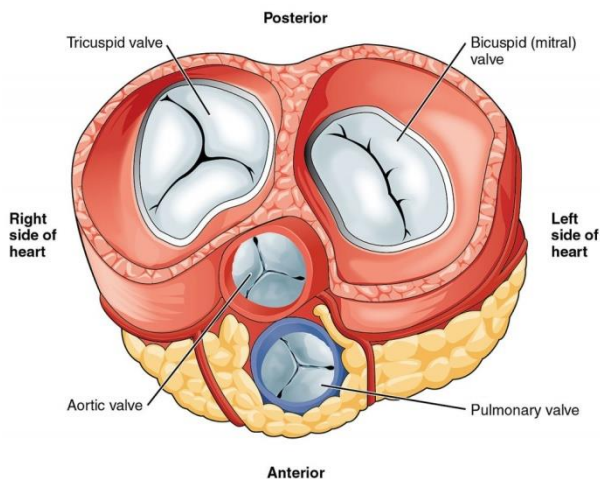
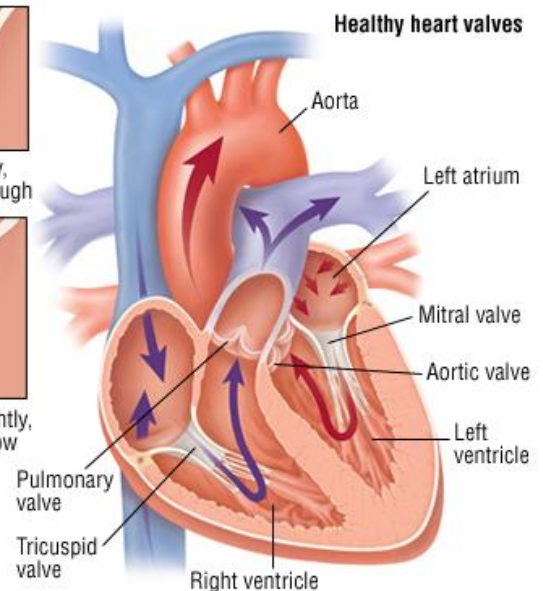
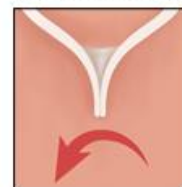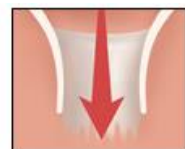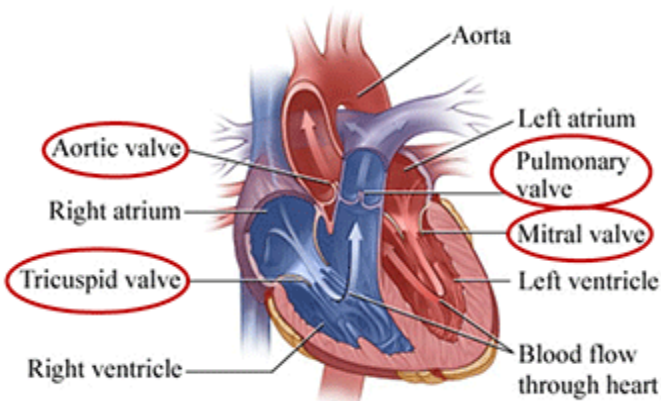
# Valvular Heart Diseases

## INTRODUCTION

Valvular Heart Diseases :

1. Aortic / Pulmonary Stenosis.
2. Aortic / Pulmonary Regurgitation.
3. Mitral / Tricuspid Stenosis.
4. Mitral/ Tricuspid Regurgitation.

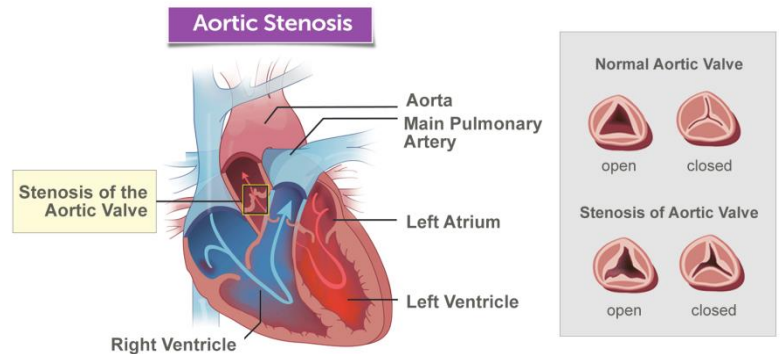
Quick review to the anatomy of valves , see the pictures below :



# Aortic Stenosis “AS”

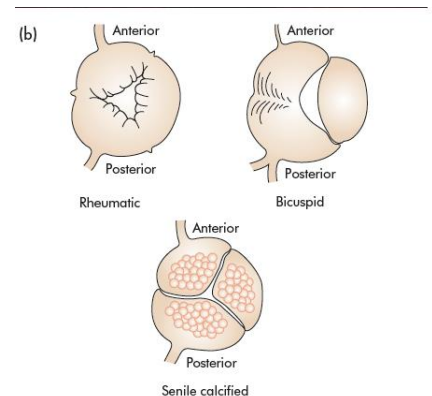
## INTRODUCTION

**Aortic stenosis** is one of the most common and most serious valve disease problems. **Aortic stenosis** is a narrowing of the **aortic** valve opening, restricts the blood flow from the left ventricle to the **aorta** and may also affect the pressure in the left atrium.



## ? ETIOLOGY

- **Infants, children, adolescents**
  1. Congenital aortic stenosis.
  2. Congenital subvalvular aortic stenosis.
  3. Congenital supravalvular aortic stenosis.
- **Young adults to middle aged**
  1. Calcification and fibrosis of congenitally bicuspid valve.
  2. Rheumatic aortic disease.
- **Middle aged to elderly**
  1. Calcification of bicuspid valve.
  2. Senile degenerative aortic stenosis.
  3. Rheumatic aortic disease.



## PATHOPHYSIOLOGY

- When the aortic valve becomes stenosed, then the left ventricle needs to create higher pressure to eject the blood outside the heart, which leads to an increase in left ventricular wall thickness or hypertrophy. This adaptive response is an attempt to normalize left ventricular wall stress in the face of increased left ventricular systolic pressure, and may maintain a normal



cardiac output, prevent left ventricular dilatation and avoid significant symptoms for a number of years.

- Eventually, myocardial function is affected and, together with insufficient left ventricular hypertrophy to normalise wall stress (load mismatch), ventricular contractility is reduced.
- When aortic stenosis is severe and cardiac output is normal, a  $>50$  mmHg gradient between peak systolic left ventricular and aortic pressure exists. As aortic stenosis worsens, cardiac output cannot increase with exertion and eventually becomes insufficient at rest. The reduction in ventricular contractility leads to an irreversible decline in left ventricular function, with dilatation and a rise in left ventricular end-diastolic pressure, to the point of overt left heart failure.
- See this video for the pathophysiology of the AS and AR >>>  
<https://www.youtube.com/watch?v=JorBOLNzfUY>



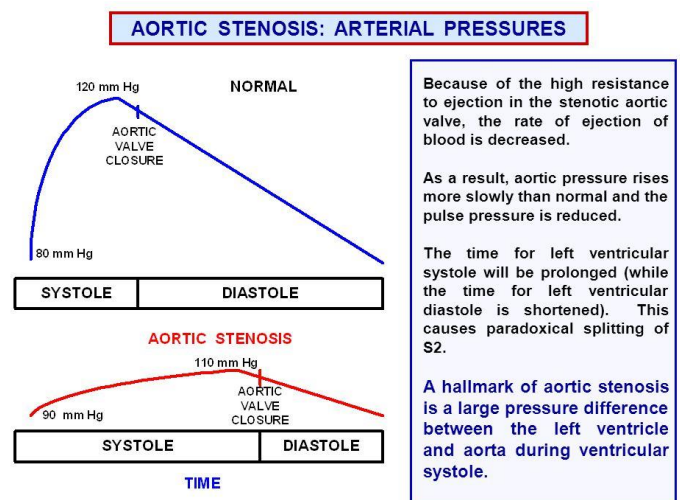
## CLINICAL FEATURES

### ➤ Symptoms of AS :

- Exertional dyspnoea.
- Angina.
- Pulmonary edema.
- Exertional syncope.>>>blood supply is enough at rest but with exercises the blood supply is not enough for the body demand .
- Sudden death.>>> sudden aortic stenosis , massive cardiomyopathy and arrhythmias .

### ➤ Signs of AS:

- Ejection systolic murmur best heard over the aortic area with radiation to the carotids. { think of it as you push blood against a closed door so that will produce a loud sound }
- Slow rising carotid pulse.
- Reduce pulse pressure. { see the Figure #1 }
- LV hypertrophy. { bcz of increase the resistance }
- Signs of LV failure (crepitations, pulmonary edema , ascites, SOB , ).

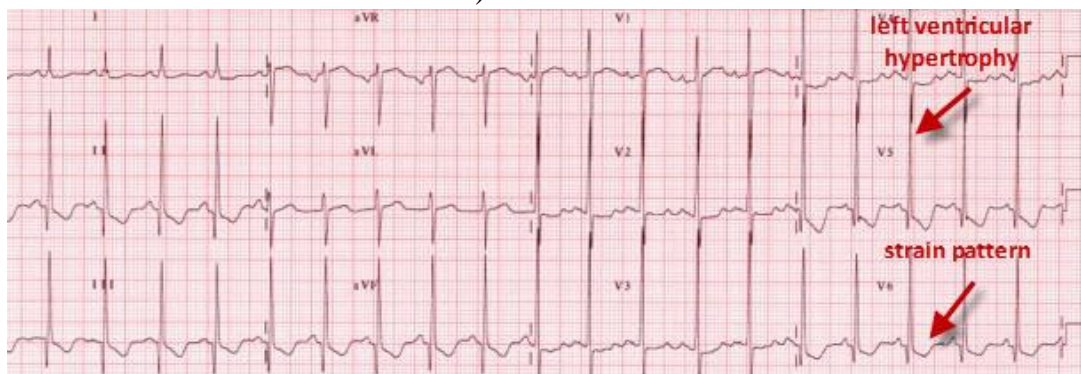
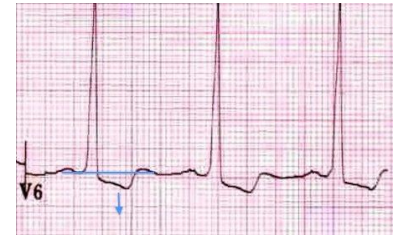



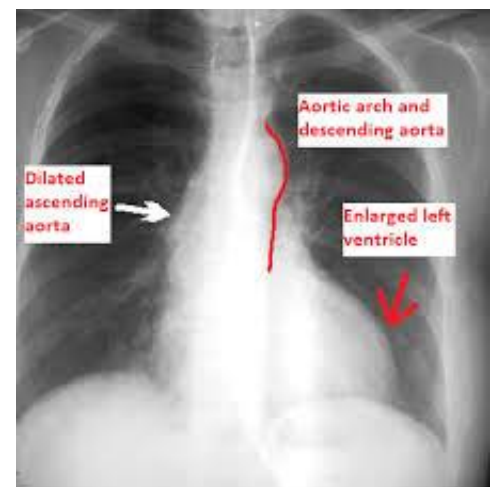
## DIAGNOSIS

### ➤ Investigations

- **ECG :**  
LVH with strain (slightly wide QRS in I,II,III and have increased amplitude)  
Large S in V2 and large R in V6 with T wave inversion in V6.
- 'strain pattern' (S–T depression with inverted T waves in the lateral leads).



- **CXR:**  
May be normal. Cardiomegaly and pulmonary congestion can be seen in the presence of left ventricular failure. Post-stenotic dilatation of the aorta is occasionally seen.



- **Echocardiography:**
  - confirms the diagnosis and, together with colour flow Doppler imaging, allows assessment of the aortic valve gradient, calculation of valve area, and evaluation of left ventricular dimensions and wall thickness
- in mild and moderate no need for surgery but in severe and critical stages the surgical replacement is must .
- **Coronary angiography:** To investigate the coronary arteries

ECHO criteria for assessment of aortic stenosis

severity	Mean gradient(mmHg)	Aortic valve area (cm <sup>2</sup> )
mild	<25	>1.5
moderate	25-50	1-1.5
severe	>50	<1
critical	>80	<0.7



## TREATMENT

- **Medical;** Medical treatment essentially is reserved for patients who have complications of AS such as **heart failure, infective endocarditis, or arrhythmias.** we should give antibiotics prophylactic!
- **Surgical;** The primary management of **symptomatic** patients with valvular AS is interventional.

Asymptomatic patients with severe AS and the following;

LV systolic dysfunction
Abnormal response to exercise (e.g. hypotension)
Ventricular tachycardia
Marked or excessive LVH (>15 mm)
Valve area <0.6 cm <sup>2</sup>
Prevention of sudden death in asymptomatic patients with none of the findings listed under asymptomatic patients with severe AS

Recommendations for Aortic Balloon Valvotomy in Adults With Aortic Stenosis

Indication
A bridge to surgery in hemodynamically unstable patients who are at high risk for AVR
Palliation in patients with serious comorbid conditions
Patients who require urgent noncardiac surgery
As an alternative to AVR

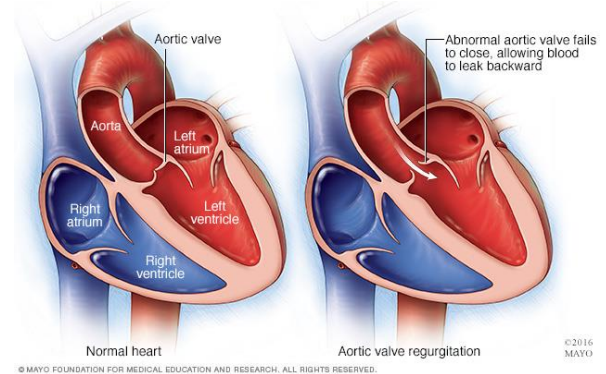
## Recommendations for Aortic Valve Replacement in Aortic Stenosis

Indication
Symptomatic patients with severe AS
Patients with severe AS undergoing coronary artery bypass surgery
Patients with severe AS undergoing surgery on the aorta or other heart valves
Patients with moderate AS undergoing coronary artery bypass surgery or surgery on the aorta or other heart valves

# Aortic Regurgitation

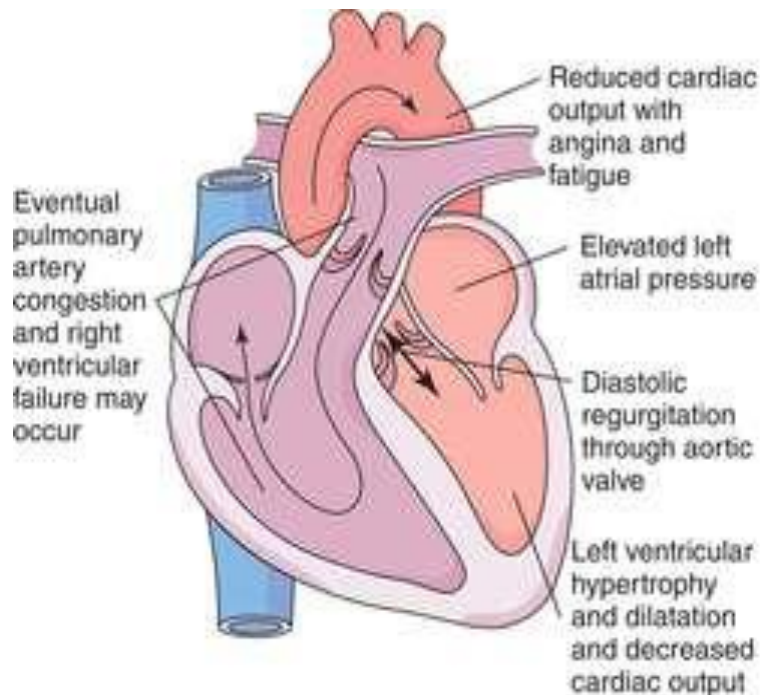
## ? ETIOLOGY

- **Congenital**  
Bicuspid valve, or disproportionate cusps
- **Acquired**  
Rheumatic disease  
Infective endocarditis  
Trauma  
Aortic dilatation: marfan syndrome, atheroma, syphilis, ankylosing spondylitis



## ⚡ PATHOPHYSIOLOGY

- **Acute** aortic regurgitation imposes a volume load on the left ventricle because of backflow. It causes a **sharp rise** in left ventricular end-diastolic pressure, **premature closure** of the mitral valve and **inadequate** forward left ventricular filling. The result is sudden haemodynamic deterioration and acute respiratory compromise { pulm.edema and congestion. }.



- In **chronic** aortic regurgitation, volume load and left ventricular end-diastolic pressure **increase gradually**, leading to **compensatory** left ventricular **dilatation and eccentric hypertrophy** to maintain adequate cardiac output. Systolic and diastolic function is **abnormal**, and **sudden** deterioration can occur.





## CLINICAL FEATURES

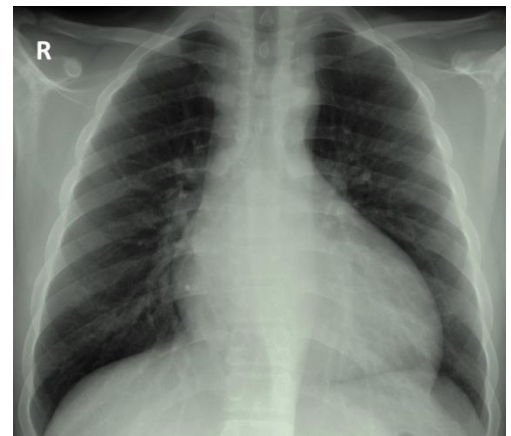
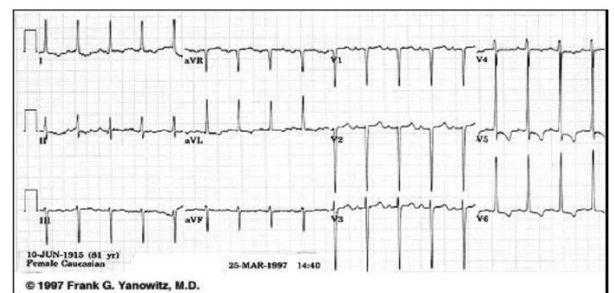
- **Symptoms :**
  - Mild AR ; asymptomatic , palpitations
  - Severe AR ; Symptoms of heart failure , angina.
- **Signs :**
  - A wide pulse pressure due to a reduction in diastolic pressure , the wide pulse pressure include visible capillary pulsation of the nail bed (Quincke's sign)
  - collapsing pulse (waterhammer pulse)
  - visible arterial pulsation in the neck (Corrigan's sign)
  - 'pistol shot' sound on auscultating over the femoral artery (Traube's sign)
  - uvular pulsation (Müller's sign).
  - Bounding peripheral pulses
  - Head nodding with pulse { de Musset s sign }
  - Early diastolic murmur best heard at the left sternal edge
  - Systolic murmur of increased stroke volume
  - Austin flint murmur (soft mid- diastolic)
  - Thrusting apex, 4TH HS
  - Signs of heart failure



## DIAGNOSIS

- **ECG :**  
LVH with strain (slightly wide QRS in I,II,III and have increased amplitude )  
Large S in V2 and large R in V6 with T wave inversion in V6  
Left atrial enlargement, Left axis deviation
- **CXR :**  
Enlarged thoracic aorta  
Bovine Heart >>> Huge cardiomegaly.
- **MRI , CT scan**

ECG in AR



- **ECHO >>> Diagnostic.**  
Dilated LV  
Hyperdynamic ventricle  
Fluttering anterior mitral leaflet  
Doppler detects reflux
- **CATH**



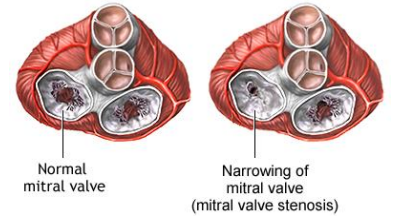
## TREATMENT

- **Medical**
  - Vasodilator therapy.
  - Treat asymptomatic patients with chronic severe AR and dilated but normal LV systolic function medically, and monitor their cases for development of indications for AVR.
  - Patients with mild AR and normal LV size require no therapy other than endocarditis prophylaxis
  - The treatment of choice for acute AR is AVR
  - .Medical therapy can be used as a bridge to surgery but should not replace it.
- **Surgical**
  - ✓ Surgical treatment of AR could be repair or replacement but the repair is very difficult . that is why the surgical treatment is almost always requires replacement of the diseased valve with a prosthetic valve. AVR is indicated when AR is beginning to cause sx or when an enlarging heart or progressive ECG changes give evidence of increasing LV overload
  - ✓ Asymptomatic patients with evidence of LV systolic dysfunction (EF <0.50) should undergo AVR.
  - ✓ Asymptomatic patients with severe AR and normal LV function but with severe LV dilatation (end-diastolic dimension >75 mm or end-systolic dimension >55 mm) should undergo AVR.
  - ✓ Preoperative predictors of poor postoperative survival and LV function include the following
    - LVESD greater than 55 mm
    - LVEF less than 0.50
    - NYHA CHF class III, IV
    - Duration of CHF symptoms longer than 12 months

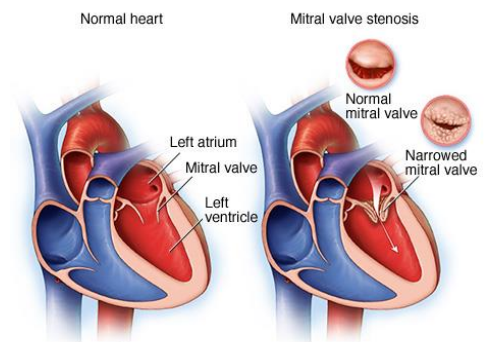
# Mitral Stenosis

## ? ETIOLOGY

- Isolated MS accounts for 25% of all rheum. Heart dis., and an additional 40% have mixed MS and MR. 2/3 of cases occurs in women
- Acquired MS is almost entirely rheum. in origin.
- long-term damage to the mitral valve and its supporting structures.
- SLE.
- Amyloidosis.
- Postsurgical acquired MS, such as MS occurring after mitral valve annuloplasty



ADAM

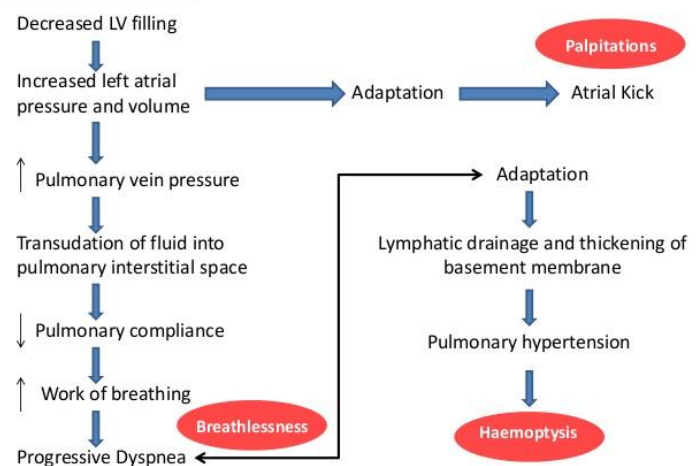


© MAYO FOUNDATION FOR MEDICAL EDUCATION AND RESEARCH. ALL RIGHTS RESERVED.

## ⚡ PATHOPHYSIOLOGY

- The **normal** adult mitral valve orifice cross sectional area is **4-6 cm<sup>2</sup>**.
- When reduced to **2 cm<sup>2</sup>**, **hemodynamically significant MS** occurs.
- **WHEN <1cm<sup>2</sup> it is critical** need surgical replacement .
- As a compensating mechanism, pulmonary vasoconstriction develops, causing pulmonary hypertension.
- Severe MS results in decreased cardiac output
- AF lead to 20% fall in CO Sudden rise in PVP caused by onset of AF lead to pulm. Edema
- Gradual rise in the pressure tends to increase in pulm vascular resistance which protect against pulm edema

### Pathophysiology





- Pulm HTN lead to RVH.
- All ptn with MS are at risk of thromboembolic disorder.
- See this video for the pathophysiology of Mitral stenosis and regurgitation >>> <https://www.youtube.com/watch?v=nY4aaBezu9o>



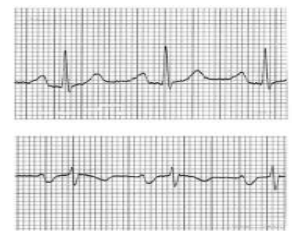
## CLINICAL FEATURES

- Symptoms:
  - Exertional dyspnea, nocturnal dyspnea, cough .
  - Ankle, leg edema, abdominal swelling (RTsided HF)
  - Sx of acute pulm edema (especially with AF, pregnancy)
  - Sx 2ndry to arterial emboli
  - Hemoptysis may be caused by rupture of dilated bronchial veins, and pink frothy sputum may be a manifestation of pulmonary edema. Both are associated with endstage and severe MS
  - Chest pain, possibly related to RV hypertension, occurs in approximately 15% of patients with MS.
  - Sx of diminished CO (fatigue, tiredness)
- Signs of MS
  - AF
  - Loud 1st heart sound, opening snap, mid diastolic
  - Murmur
  - Signs of raised pulm capillary pressure (crepitations, pul edema, effusions)
  - Signs of pul HTN
- In severe: MS Soft S1 because of decreased mobility of the mitral leaflets

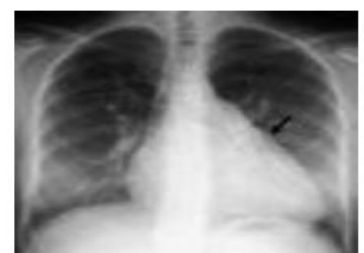

## DIAGNOSIS

- ECG
  - LA hypertrophy if not in AF . Left atrial enlargement is illustrated by increased P wave duration in lead II and by the prominent negative P terminal force in lead V1.
  - RVH
- CXR
  - Chest radiograph of a patient with mitral stenosis shows pulmonary hypertension, mild cardiomegaly and enlargement of the left atrium and pulmonary artery



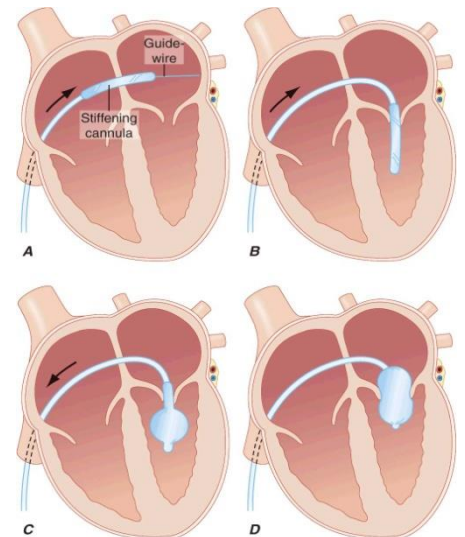
CXR



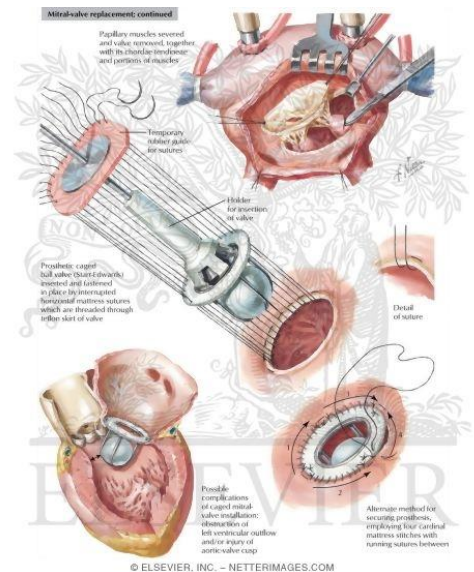
- ECHO >> diagnostic .
  - Thickened immobile cusps.
  - Reduced rate of diastolic filling.
  - Reduced valve area
  - Huge dilatation of the L.t atrium , the surface area of the valve is decreased.
- CARDIAC CATH
  - obtain direct measurement of the pressure gradient across the mitral valve as well as pulmonary artery pressure and pulmonary vascular resistance.
  - More commonly, it is undertaken to perform percutaneous balloon valvuloplasty

## TREATMENT

- Medical
  - Asymptomatic patients with mild MS require yearly follow-up.
  - For the patient with signs or symptoms of CHF, diuretics may provide benefit.
  - RX of Tachyarrhythmias
  - Electrophysiologic ablation of atrial fibrillation or flutter circuits may be performed in the catheterization laboratory.
- Percutaneous mitral balloon valvuloplasty
  - Indications for this procedure are similar to those for surgery, including:
    - CHF unresponsive to medical management
    - asymptomatic patients with a pulmonary artery (PA) HTN .
    - systolic pressure of 50 mm Hg or greater.
  - In some centers, the procedure is successful in 80- 90% of selected cases. The procedural mortality rate is 1-2%.
  - the treatment of choice if appropriate criteria are fulfilled which are:
    - Significant sx
    - Isolated MS
    - No (or trivial) MR
    - Mobile, non-calcified valve/sub-valve apparatus on echo
    - LA free of thrombus.



- Through the femoral artery to reach the heart then inflate the balloon to increase the surface area of the valve .
- Surgical
  - Indications:
    - a. Symptomatic mitral stenosis especially if peripheral emboli
    - b. Mitral valve area less than 1 cm<sup>2</sup>
  - Options :
    - a. Mitral valvotomy Commissurotomy consists of an incision of fused mitral valve commissures and shaving of thickened mitral valve leaflets
    - c. Fused chordae tendineae and papillary muscles can be divided to relieve subvalvular stenosis.
    - d. Supravalvular tissue contributing to the MS should be resected.
  - Mitral valve replacement with mechanical valve or bioprosthesis

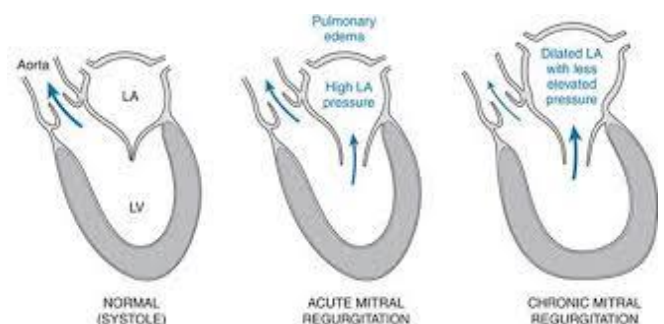
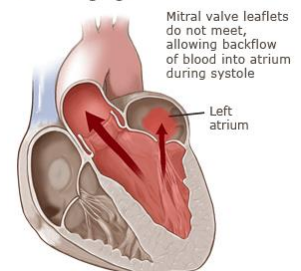


## Mitral Regurgitation

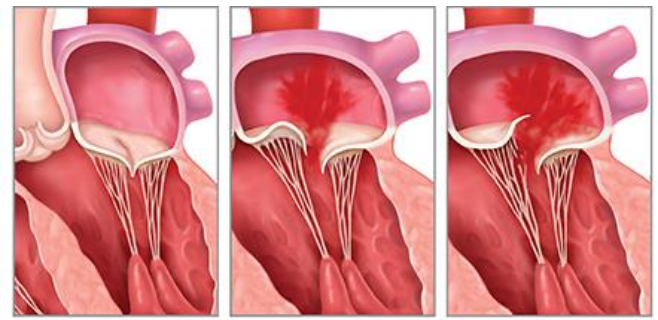
### ? ETIOLOGY

- Acute MR :
  1. Ruptured chordae or papillary muscle due to acute myocardial infarction or trauma
  2. Perforation of the mitral valve leaflet
  3. Acute failure of a prosthetic valve
- Chronic MR :
  1. Mitral valve prolapsed 5%
  2. Rheumatic heart disease >> common .
  3. Coronary artery disease
  4. Annular calcification

Mitral Regurgitation



5. LV dilatation
6. Connective-tissue disorder
7. Prosthetic valves



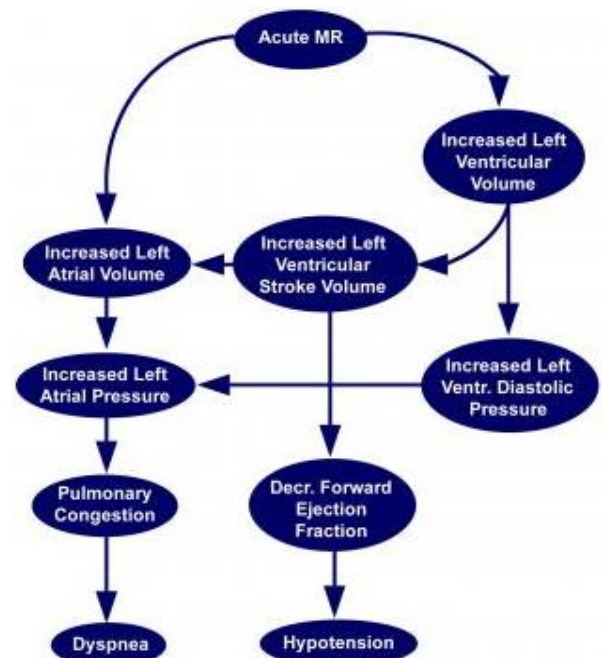
Normal Valve

Degenerative MR—  
Prolapse

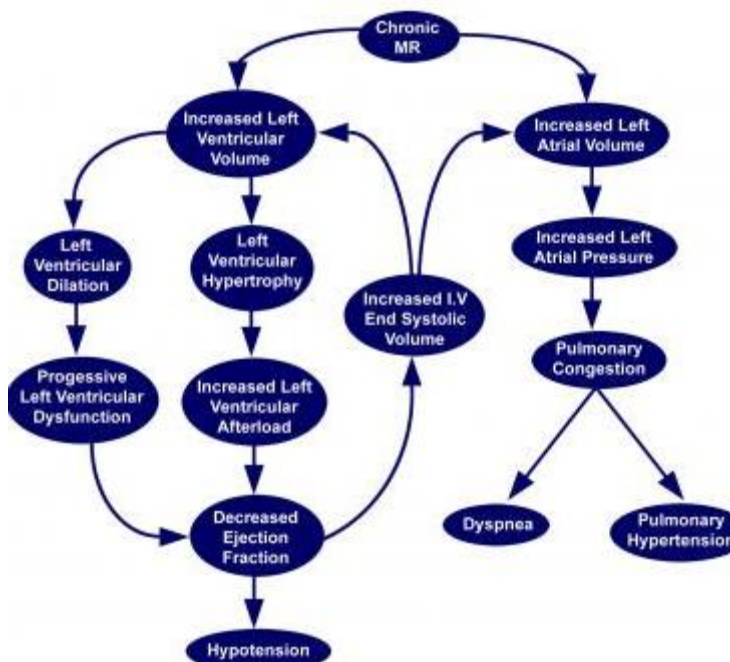
Degenerative MR—  
Flail

## ⚡ PATHOPHYSIOLOGY

- In acute MVR, the ventricular ejection fraction reflux into the left atrium. The inability of the atrium and ventricle to immediately dilate, resulting in elevated left atrial and pulmonary venous pressures and acute pulmonary edema. The net reduction in forward stroke volume reduces systemic perfusion, can result in hemodynamic deterioration, and can lead to cardiogenic shock.



- In chronic MVR, the distensibility of the LA and LV are increased over time. This dilatation of the left atrium decreases left atrial pressures, thus increasing preload. The left ventricle dilates and, hypertrophied generates a larger stroke volume without a significant rise in wall stress.







## CLINICAL FEATURES

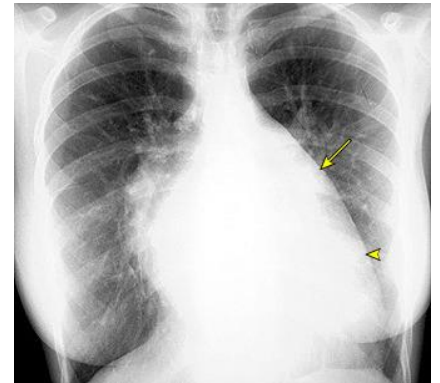
### Symptoms

- Acute MR
  - Sx of acute pulm edema and reduced CO
- Chronic progressive MR
  - Exertional dyspnea, nocturnal dyspnea, palpitations(AF, atrial flutter, increased stroke volume)
  - Sx of pulm edema and Signs of pulm HTN
  - Sx of diminished CO
  - Sx of right sided HF
  - Cardiomegaly- displaced hyperdynamic apex beats
  - Apical systolic murmur, thrill , Soft s1, apical s3
  - Signs of raised pulm capillary pressure (crepitations, pulm edema, effusions)



## DIAGNOSIS

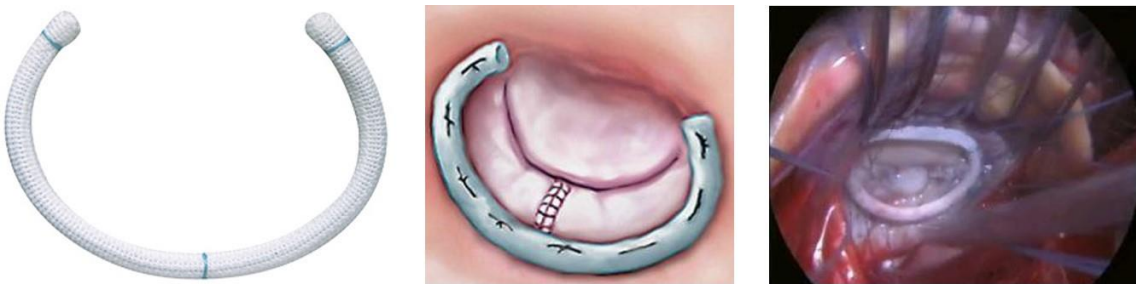
- ECG
  - LAH (if not in AF)
  - LVH
- CXR
  - Enlarged LA, LV , marked cardiomyopathy
  - Signs of pulm venous HTN
  - Signs of pulm edema if acute
- ECHO
  - Dilated LA, LV
  - Dynamic LV(UNLESS AF PREDOMINATE)
  - Regurgitation detected on Doppler.
- Cardiac cath
  - Dilated LV, LA
  - Pulm HTN (in chronic MR)



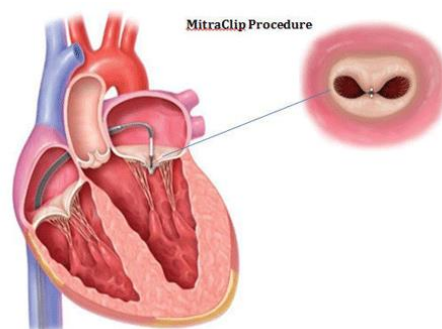
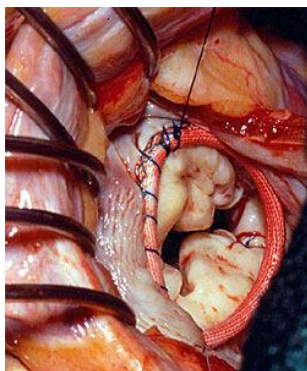
## TREATMENT

- Medical
  - Any patient with acute or chronic mitral valve regurgitation with hemodynamic compromise should be evaluated for acute myocardial infarction. Afterload-reducing agents

- If atrial fibrillation is encountered, digitalis therapy is considered
- Prophylactic antibiotics are administered prior to any interventional treatment
- **SURGICAL**
  - Here we are trying to repair not to replace as much as we can but in some conditions as in Rheumatic disease repair is impossible .
  - Indications for surgical Intervention:
    - I. Acute MR with congestive heart failure or cardiogenic shock
    - II. Acute endocarditis
    - III. Class III/IV symptoms (ie, patient symptomatic while at rest or with minimal activity)
    - IV. Systemic emboli
  - Surgical options
    - i. Mitral valve reconstruction with mitral annuloplasty, quadrantic segmental resection, shortening of the elongated chordae, or posterior leaflet resection.



An annuloplasty ring is used to strengthen the mitral valve repair



Courtesy of Abbott Vascular. © 2013 Abbott Laboratories. All Rights Reserved.


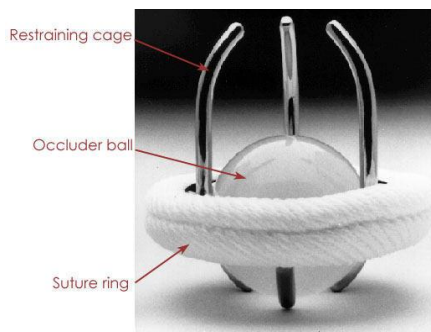
- ii. Mitral valve replacement with either a mechanical valve (requiring lifelong anticoagulation) or a bioprosthetic porcine valve.

# Prosthetic heart valves

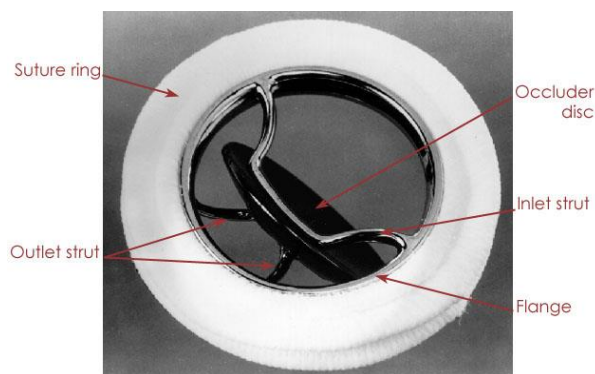
- The two main prosthetic valve designs include:
- Mechanical.
  - bioprosthetic(tissue) heart valves

## Mechanical valves

- Types :
  - ball and cage
  - bileaflet



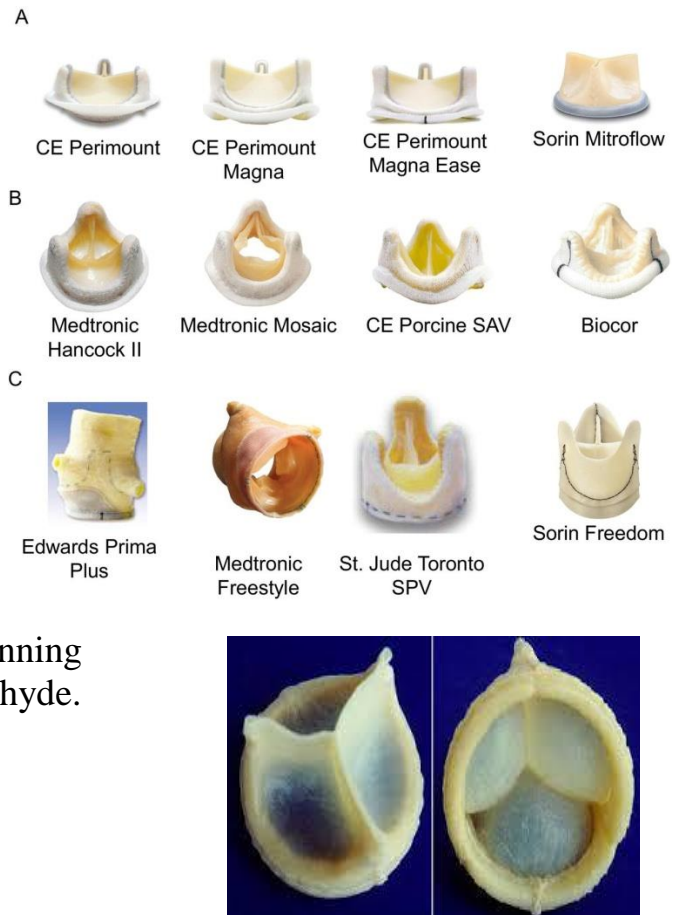
- tilting-disc valve





# Bioprosthetic Valves

- Human tissue valves:
  - Autograft
  - Homograft
- Animal tissue valves:
  - Heterograft or Xenograft
  - The most commonly used animal tissues are: porcine, which is valve tissue from a pig, and bovine pericardial tissue, which is from a cow.
  - The leaflet valve tissue of the animals is inspected, and the highest quality leaflet tissues are then preserved. They are then stiffened by a tanning solution, most often glutaraldehyde.



## Comparison

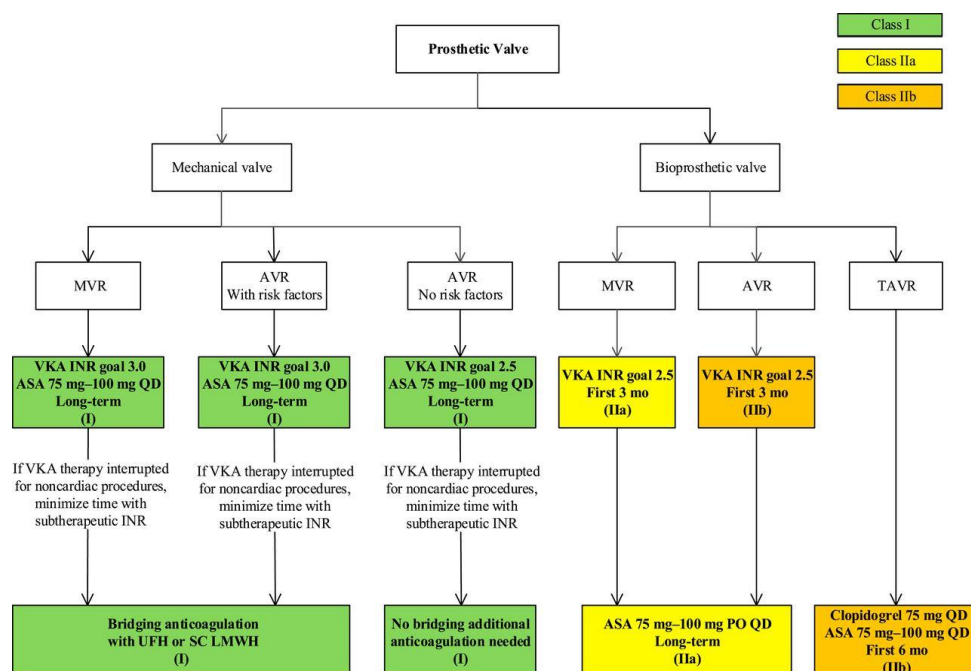
- Mechanical valves
  - Readily available
  - Good durability
  - Require life-long anticoagulation
  - Risk of endocarditis
- Heterografts
  - Readily available
  - Limited lifespan (aortic valves ~ 15 years, mitral valve ~8 years)
  - Limited duration of anticoagulation
- Homografts
  - Not readily available
  - Do not require anticoagulation
  - Long-term outcome uncertain

# How to choose a valve

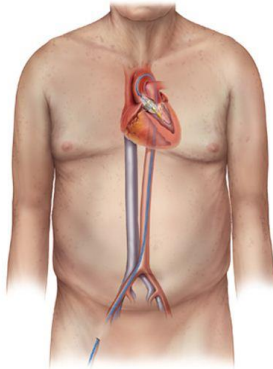
- Mechanical valve in patients < 60 years.
- Tissue valves in patients > 65 years
- Tissue valves in patients whose life expectancy is < 10 year\
- Tissue valve in patients who have problems which are likely to cause life threatening bleeding.

## • NOTES :

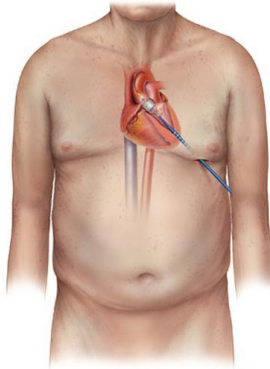
- in case of severe Aortic congenital abnormality replace it with the pulmonary valve .
- INR Guideline :



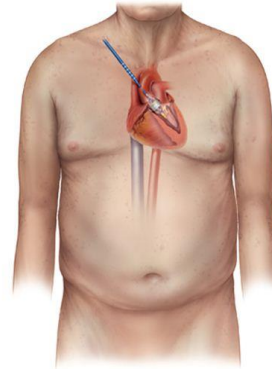
- Trans catheter aortic valve replacement :  
It is very expensive so we just use it in highly risk patients.  
Trans femoral { the most common }, Transaxillary, Transapical or Trans aortic .



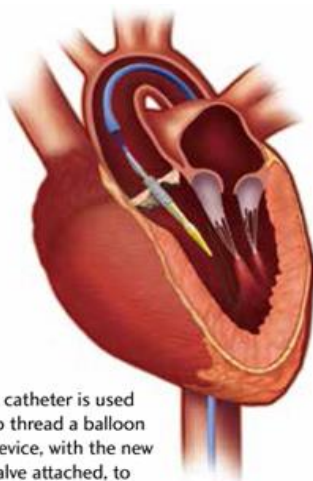
Trans-femoral Approach



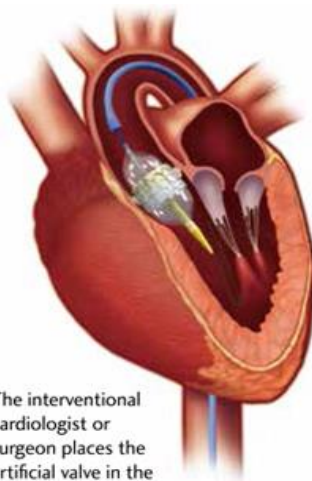Trans-apical Approach



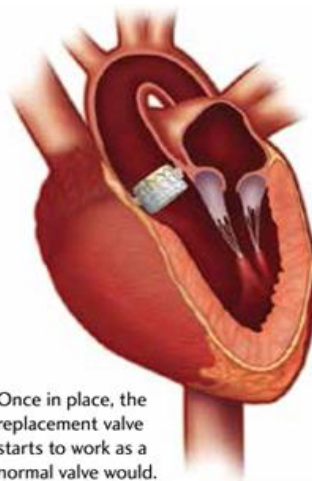Trans-aortic Approach



A catheter is used to thread a balloon device, with the new valve attached, to the diseased valve.



The interventional cardiologist or surgeon places the artificial valve in the diseased valve and inflates the balloon.



Once in place, the replacement valve starts to work as a normal valve would.

# Congenital heart diseases

## INTRODUCTION

✦ CHD are the most common category of congenital structural malformation.

- Incidence in Jordan is 8-10/1000 live births, approximately 2000/ year.
- Incidence is more in :-
  1. Premature
  2. Abortions
  3. still births

## ? ETIOLOGY

✦ Multifactorial inheritance pattern mostly

✦ Chromosomal abnormality is seen on 5-10% of cases:

- **Trisomy 21** (50%) > A-V canal, VSD, ASD, others.
- **Trisomy 18** (80%) > VSD, ASD, others.
- **Trisomy 13** (40%) > VSD, ASD, PDA, others.
- **Turner syndrome** (xo) > Bicuspid aortic valve and co-ao

✦ Adverse maternal conditions (environmental):

- **Maternal infections** > Rubella: PDA, PS.
- **Maternal diseases** > PKU- VSD, ASD.
- **DM: left septal hypertrophy**
- **Drugs** Valproate effect- co ao left heart hypoplasia
- **Fetal alcohol syndrome** > VSD, ASD, CO-AO.
- **Advance maternal age.**

✦ Syndrome complexes:

- **VACTREL syndrome:** Vertebral, Anorectal, Cardiac (VSD, TOF and others), tracheal, Renal, Oesophageal and Limb abnormalities.
- **CHARGE syndrome:** Coloboma, Heart (VSD, TOF, A-V canal), Atresia choanal, Retardation, Genital, Ear abnormalities.
- **Kartagener syndrome:** Dextrocardia
- **TAR syndrome**



## CLINICAL FEATURES

✦ CHD are either cyanotic or acyanotic:

- **Causes of cyanotic CHD:** impaired blood flow to lungs, impaired blood flow from lungs to heart, too much mixing of oxygenated and deoxygenated blood, or if systemic and pulmonary do not mix

The cause	Examples
Blood flow from right heart to lungs impaired	<ul style="list-style-type: none"> <li>➤ Pulmonary atresia</li> <li>➤ Critical Pulmonary stenosis</li> <li>➤ Pulmonary stenosis</li> </ul>
Blood flow from Lungs to left atrium impaired	<ul style="list-style-type: none"> <li>➤ Total anomalous pulmonary venous drainage (TAPVD).</li> <li>➤ Partial anomalous pulmonary venous drainage (PAPVD)</li> </ul>
Too much mixing of oxygenated and deoxygenated blood	<ul style="list-style-type: none"> <li>➤ Double outlet syndromes</li> <li>➤ Large VSDs</li> </ul>
Systemic and pulmonary blood flow unable to mix	<ul style="list-style-type: none"> <li>➤ Transposition of great arteries</li> </ul>
Mixed	Fallot's tetralogy

- **Causes of Acyanotic CHD:** Left sided heart problems, extra tubes and holes, Narrowing of valves

The cause	Examples
Left sided heart lesions	<ul style="list-style-type: none"> <li>➤ Hypoplastic left heart syndrome</li> <li>➤ Coarctation of aorta</li> </ul>
Extra tubes	<ul style="list-style-type: none"> <li>➤ Patent ductus arteriosus</li> </ul>
Extra holes	<ul style="list-style-type: none"> <li>➤ ASD</li> <li>➤ VSD</li> <li>➤ Atrioventricular septal defect (AVSD)</li> </ul>

- Acyanotic are further classified into:
  1. **Acyanotic CHD with volume load (L-R shunts-):** ASD, VSD, PDA & AV Canal
  2. **Acyanotic CHD with pressure load:** Ventricular outflow obstruction, Pulmonary & aortic valve lesions, aortic coarctation & pulmonary stenosis.



## TREATMENT

⚡ Treatment Strategies:

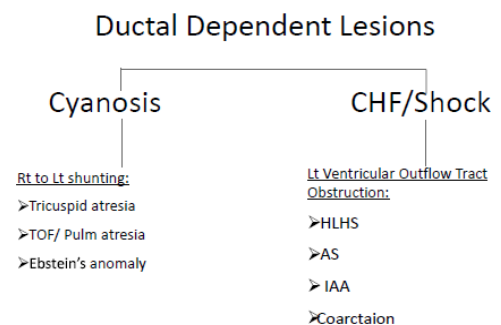
1. Stabilizing Treatment
2. Palliative Treatment
3. Definitive Treatment

### 1-Stabilizing strategy:

⚡ Most congenital heart disease is diagnosed in utero by ultrasound during routine prenatal care.

⚡ Neonates present with signs of:

1. Shock
2. Cyanosis
3. CHF
4. or a combination of the three and typically present at 2 weeks of age as the ductus arteriosus closes.



⚡ **Congenital heart disease presenting with cyanosis at or soon after birth:**

1. Pulmonary atresia/VSD (1:3500 live births)
  2. Transposition of Great vessels (1:3500)
  3. Pulmonary atresia /Intact ventricular septum
  4. Critical pulmonary stenosis
- Prostaglandin administration Maintain a patent ductus arteriosus,  
**Intravenous infusion Prostaglandin E1(alprostadil)/ Oral  
 prostaglandins: Prostaglandin E2**

⚡ **Congenital heart disease presenting with shock in the neonate:**

1. Coarctation
  2. Interrupted aortic arch
  3. Critical aortic stenosis
  4. Hypoplastic left heart syndrome
- Congenital heart disease must be excluded in all neonates presenting with shock or cardiac failure.
- Careful comparison of upper and lower limb pulses essential in all neonates repeat if neonate becomes ill later
- Early maintenance of ductal patency can be lifesaving.

### ✦ **CHF in the newborn suspected of having congenital heart:**

- Treatment of CHF in the newborn suspected of having congenital heart disease may require intubation and positive pressure ventilation, and gentle diuresis.
- Because structural heart disease and congenital rhythm abnormalities can cause CHF, electrocardiography early in the resuscitation may aid in the diagnosis.
- Supraventricular tachycardia in infants is suggested by a narrow complex tachycardia with rates greater than 220 beats per minute.

## **2. Palliative options**

1. Increase pulmonary blood flow - Aortopulmonary shunt.
2. Decrease pulmonary artery blood flow - PA banding
3. Improve mixing - atrial septectomy
4. Reduce ventricular work - Glenn shunt

## **3. Definite treatment**

1. 2 ventricle circulation
2. 1 ventricle circulation

We'll start with Acyanotic Congenital Heart Disease:



# Atrial Septal Defect (ASD)

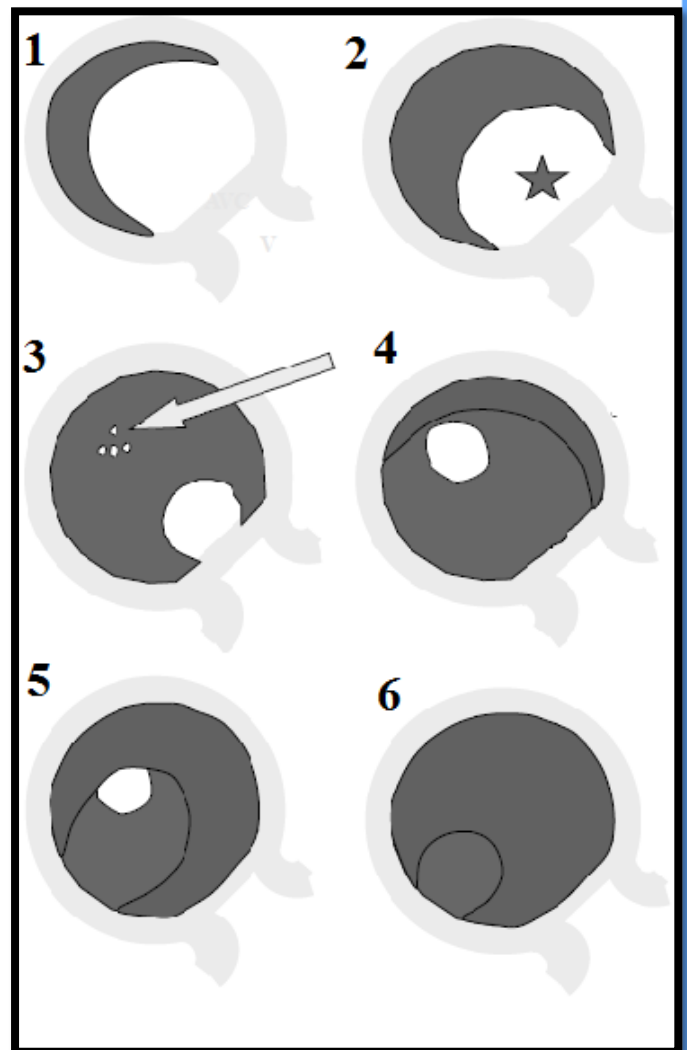
## INTRODUCTION

✦ **ASD:** Is an acyanotic CHD with volume load (L-R shunts-), that results from abnormal connection between two atria.

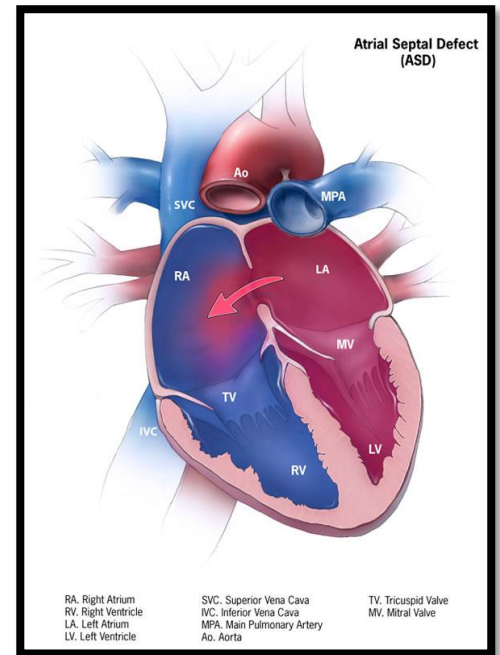
## PATHOPHYSIOLOGY

✦ Formation of the interatrial septum occurs in several stages.

1. The first is the **development of the septum primum (figure 1)**; a crescent-shaped piece of tissue forming the initial divider between the right and left atria. Because of its crescent shape, the septum primum does not fully occlude the space between left and right atria; the opening that remains is called the **foramen primum (figure 2, the star)**. During fetal development, this opening allows blood to be shunted from the right atrium to the left.
2. As the septum primum grows, the foramen primum progressively narrows. Before the foramen primum is completely occluded, a second opening called the **foramen secundum (figure 3, the arrow)** begins to form in the septum primum. The foramen secundum allows continued shunting of blood from the right atrium to the left.



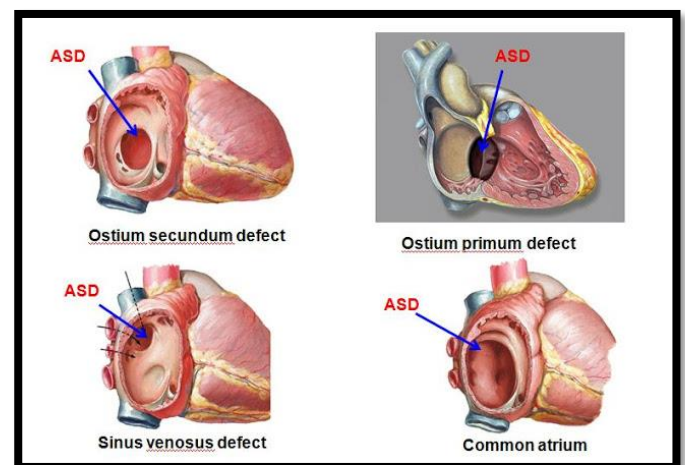
3. To the right of the septum primum, the **septum secundum** (figure 4) begins to form. This thick, muscular structure initially takes on the same crescent shape as the septum primum, except that it originates anteriorly, whereas the septum primum originates posteriorly. As the septum secundum grows, it leaves a small opening called the **foramen ovale** (figure 5). The foramen ovale is continuous with the foramen secundum, again providing for continued shunting of blood.
4. The ostium secundum progressively enlarges and the size of the septum primum diminishes. Eventually, the septum primum is nothing more than a small flap that covers the foramen ovale on its left side. This flap of tissue is called **the valve of the foramen ovale** (figure 5). It opens and closes in response to pressure gradients between the left and right atria. When the pressure is greater in the right atrium, the valve opens; when the pressure is greater in the left atrium, the valve closes. Because the lungs are nonfunctional in fetal life, pressure in the pulmonary circulation is greater than that of the systemic circulation. Consequently, the right atrium is generally under higher pressures than the left atrium, and the valve of the foramen ovale is normally open.



✚ ASD is an opening in the atrial septum permitting free communication of blood between the atria. Seen in 10% of all CHD.

✚ There's 3 types of ASD:

- **Secondum ASD** at the Fossa Ovalis, most common.
- **Primum ASD**: lower in position & is a form of ASVD, MV cleft.
- **Sinus venosus ASD**: high in the atrial septum, associated w/partial anomalous venous return & the least common.





## CLINICAL FEATURES

### ⚡ Symptoms:

- Rarely presents with signs of CHF or other cardiovascular symptoms.
- Most are asymptomatic but may have easy fatigability or mild growth failure.
- Cyanosis does not occur unless pulmonary HTN is present.

### ⚡ Physical examination:

- Hyperactive precordium, RV heave, fixed widely split S2.
- II-III/VI systolic ejection murmur at LSB (increased flow across the pulmonary valve,).
- Mid-diastolic murmur heard over LLSB (increased flow across the tricuspid valve).



## TREATMENT

⚡ Surgical or catheterization laboratory closure is generally recommended for secundum ASD.

- Closure is performed electively between ages 2 & 5 yrs to avoid late complications.
- Surgical correction is done earlier in children with CHF or significant Pulm HTN.
- Once pulmonary HTN with shunt reversal occurs this is considered too late

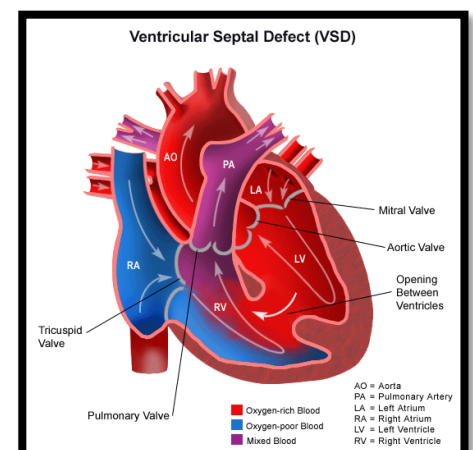
⚡ There's no need for endocarditis prophylaxis in ASD.

## Ventricular Septal Defect (VSD)



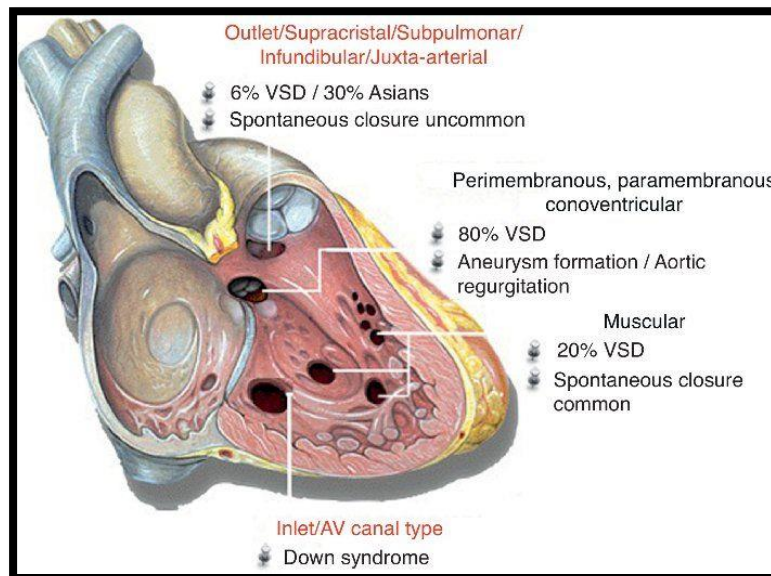
## INTRODUCTION

⚡ VSD is an abnormal opening in the ventricular septum, which allows free communication between the Rt & Lt ventricles. Accounts for 25% of CHD.



✦ It has 4 types:

- **Perimembranous VSD:** Most common.
- **Infundibular VSD:** involves the RV outflow tract.
- **Muscular VSD:** can be single or multiple.
- **Inlet VSD:** almost always involves AV valvular abnormalities.



## ⚡ PATHOPHYSIOLOGY

✦ The left to right shunt occurs secondary to PVR being < SVR, not the higher pressure in the LV.

- This leads to elevated RV & pulmonary pressures & volume hypertrophy of the LA & LV.

## 🔍 CLINICAL FEATURES

✦ **Symptoms:**

- **If Small -moderate VSD (3-6mm):** are usually asymptomatic and 50% will close spontaneously by age 2yrs.
- **Moderate - large VSD:** almost always have symptoms and will require surgical repair.

✦ **Eisenmenger's syndrome:** is defined as the process in which a long-standing left-to-right cardiac shunt caused by a congenital heart defect (typically by a ventricular septal defect, atrial septal defect, or less commonly, patent ductus arteriosus) causes pulmonary hypertension. and eventual reversal of the shunt into a cyanotic right-to-left shunt.

### ⚡ Signs:

- II-III/VI harsh holosystolic murmur heard along the LSB, more prominent with small VSD, maybe absent with a very Large VSD.
- Prominent P2, Diastolic murmur.
- CHF, FTT, Respiratory infections, exercise intolerance
- hyperactive precordium. Symptoms develop between 1-6 months



## TREATMENT

⚡ **Small VSD:** no surgical intervention, no physical restrictions, just reassurance and periodic follow-up and endocarditis prophylaxis.

### ⚡ Symptomatic VSD:

- Medical treatment initially with afterload reducers & diuretics.
- Surgical treatment: Indicated for closure of a VSD associated with CHF & FTT or pulmonary hypertension. **Or** in Patients with cardiomegaly, poor growth, poor exercise tolerance, or other clinical abnormalities and a qP/qS > 2:1 typically undergo surgical repair at 3-6 months

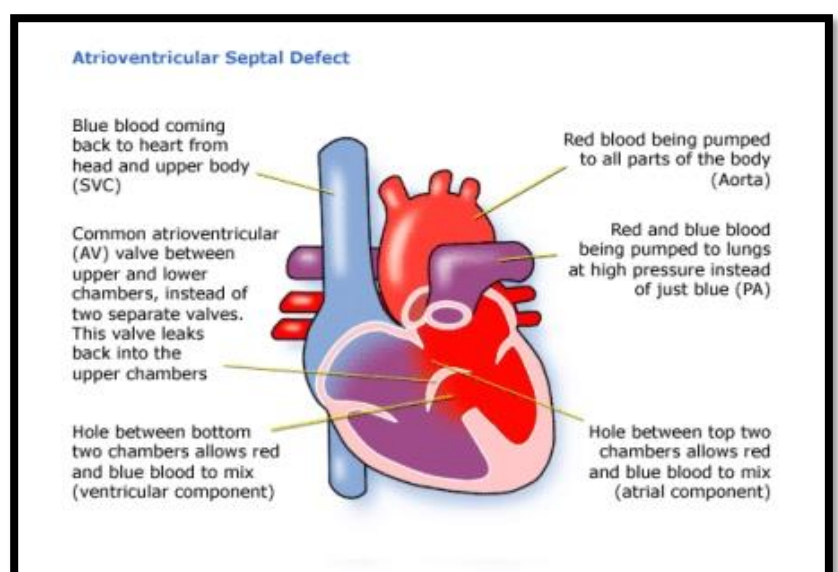
# Atrioventricular Septal Defect



## INTRODUCTION

⚡ (Atrioventricular Septal Defect) AVSD results from incomplete fusion the endocardial cushions, which help to form the lower portion of the atrial septum, the membranous portion of the ventricular septum and the septal leaflets of the tricuspid and mitral valves.

- They account for 4% OF ALL CHD.





- AVSD is associated with Down's syndrome, it's seen in 20-25% of cases.

✦Types of AVSD:

Complete Form	Incomplete Form
<ul style="list-style-type: none"> <li>• Low primum ASD continuous with a posterior VSD.</li> <li>• Cleft in both septal leaflets of TV/MV.</li> <li>• Results in a large L to R shunt at both levels.</li> <li>• TR/MR, Pulm HTN with increase in PVR.</li> </ul>	<ul style="list-style-type: none"> <li>• Any one of the components may be present.</li> <li>• Most common is primum ASD, cleft in the MV &amp; small VSD.</li> <li>• Hemodynamics are dependent on the lesions.</li> </ul>



## CLINICAL FEATURES

- Incomplete AVSD maybe indistinguishable from ASD → usually asymptomatic.
- Congestive heart failure in infancy.
- Recurrent pulmonary infections.
- Failure to thrive.
- Exercise intolerance, easy fatigability.
- Late cyanosis from pulmonary vascular disease with Right to Left shunt.
- Hyperactive precordium
- Normal or accentuated 1st heart sound
- Wide, fixed splitting of S2
- Pulmonary systolic ejection murmur w/thrill
- Holosystolic murmur at apex with radiation to axilla
- Mid-diastolic rumbling murmur at LSB
- Marked cardiac enlargement on CX-Ray.



## TREATMENT

✦Surgery is always required.

- Treat congestive symptoms.
- Correction is done during infancy to avoid irreversible pulmonary vascular disease.
- Mortality low (incomplete 1-2%) (5% with complete).

# Patent Ductus Arteriosus



## INTRODUCTION

⚡ PDA is the Persistence of the normal fetal vessel that joins the PA to the Aorta.

- Ductus arteriosus closes normally in the 1st week of life.
- Accounts for 10% of all CHD, seen in 10% of other congenital heart lesions and can often play a critical role in some lesions.
- Female: Male ratio of 2:1
- Often associated with coarctation of aorta & VSD.
- It's associated with maternal Rubella infection.



## PATHOPHYSIOLOGY

⚡ As a result of higher aortic pressure, blood shunts from left to right through the ductus from Aorta to PA.

- Extent of the shunt depends on size of the ductus & PVR:SVR.
- In Small PDA, pressures in PA, RV, RA are normal.
- In large PDA, PA pressures are equal to systemic pressures. In extreme cases 70% of CO is shunted through the ductus to pulmonary circulation.
- Leads to increased pulmonary vascular disease.



## CLINICAL FEATURES

⚡ Small PDA are usually asymptomatic>

⚡ Large PDA results in symptoms of CHF:

- growth restriction, FTT.
- Bounding arterial pulses
- Widened pulse pressure
- Enlarged heart, prominent apical impulse
- Classic continuous machinery systolic murmur
- Mid-diastolic murmur at the apex.





## TREATMENT

⚡ **Indomethacin**, inhibitor of prostaglandin synthesis can be used in premature infants.

⚡ PDA requires surgical or catheter closure.

- Closure is required treatment heart failure & to prevent pulmonary vascular disease.
- Usually done by ligation & division or intra vascular coil.
- Mortality is < 1%

# Obstructive Heart Lesions

## 1- Pulmonary Stenosis



## INTRODUCTION

⚡ **Pulmonary Stenosis** is obstruction in the region of either the pulmonary valve or the subpulmonary ventricular outflow tract.

- Accounts for 7-10% of all CHD.
- Most cases are isolated lesions
- Maybe bicuspid or fusion of 2 or more leaflets.
- Can present with or without an intact ventricular septum.
- It's associated with **Noonan's syndrome**, secondary to valve dysplasia.



## PATHOPHYSIOLOGY

⚡ Right ventricular pressure hypertrophy → RV failure.

- RV pressures may increase systemic pressure.
- Post-stenotic dilation of main PA.
- With intact septum & severe stenosis R-L shunt through PFO cyanosis.
- **Cyanosis** is indicative of Critical PS.



## CLINICAL FEATURES

⌘ Depends on the severity of obstruction.

- Asymptomatic with mild PS < 30mmHg.
- Mod-severe: 30-60mmHg, > 60mmHg

⌘ Prominent jugular a-wave, RV lift

⌘ Split 2nd hrt sound with a delay

⌘ Ejection click, followed by systolic murmur.

⌘ Heart failure & cyanosis seen in severe cases



## TREATMENT

⌘ In mild PS, no intervention required, close follow-up.

⌘ Moderate/severe require relieve of stenosis.

- Balloon valvuloplasty, treatment of choice.
- Surgical valvotomy is also a consideration.

## 2- Congenital Aortic Stenosis



## INTRODUCTION

⌘ Aortic Stenosis is an obstruction to the outflow from the left ventricle at or near the aortic valve that causes a systolic pressure gradient of more than 10mmHg.

- Accounts for 7% of CHD.

⌘ types of pediatrics (congenital) Aortic stenosis:

1. **Valvular Aortic stenosis:** the most common
2. **Supravalvar Aortic Stenosis:** involves the ascending aorta is the, least common, associated with Williams Syndrome.
3. **Subvalvar Aortic Stenosis:** involves the left outflow tract.



## PATHOPHYSIOLOGY

⚡ Pressure hypertrophy of the LV and LA with obstruction to flow from the LV.

- Mild AS → 0-25mmHG
- Moderate AS → 25-50mmHg
- Severe AS → 50-75mmHg
- Critical AS → > 75mmHg



## CLINICAL FEATURES

⚡ Symptoms:

- Mild AS → may present with exercise intolerance, easy fatigability, but usually asymptomatic.
- Moderate AS → Chest pain, dyspnea on exertion, dizziness & syncope.
- Severe AS → Weak pulses, left sided heart failure, **sudden death!**

⚡ Signs:

- LV thrust at the Apex.
- Systolic thrill at right base/suprasternal notch.
- Ejection click, III-IV/VI systolic murmur at LSB
- with radiation to the carotids.



## TREATMENT

⚡ Because surgery does not offer a cure it is reserved for patients with symptoms and a resting gradient of 60-80mmHg.

- For subaortic stenosis it's reserved for gradients of 40-50 mmHg because of its rapidly progressive nature.
- Balloon valvuloplasty is the standard of treatment.

⚡ Prognosis:

- Aortic insufficiency & re-stenosis is likely after surgery and may require valve replacement.
- Activity should not be restricted in Mild AS.
- Mod-severe AS, no competitive sports.

### 3- Coarctation of the Aorta



#### INTRODUCTION

✦ **Coarctation:** is narrowing of the aorta at varying points anywhere from the transverse arch to the iliac bifurcation.

- 98% of coarctations are juxtaductal
- Male: Female ratio 3:1.
- Accounts for 7 % of all CHD.
- It's associated with Bicuspid aortic valve, seen in > 70% of cases.
- It's associated with Turner's syndrome.



#### CLINICAL FEATURES

- Classic signs of coarctation are diminution or absence of femoral pulses.
- Higher BP in the upper extremities as compared to the lower extremities.
- 90% have systolic hypertension of the upper extremities.
- Pulse discrepancy between right & left arms.
- With severe coarctation → LE hypoperfusion, acidosis, HF and shock.
- Differential cyanosis if ductus is still open
- II/VI systolic ejection murmur at LSB.
- **Cardiomegaly, rib notching on X-ray.**



#### TREATMENT

✦ With severe coarctation maintaining the ductus with prostaglandin E is essential.

✦ Surgical intervention, to prevent LV dysfunction.

✦ Angioplasty is used by some centers.

- Re-coarctation can occur, balloon angioplasty is the procedure of choice.

**Now we will start with cyanotic heart diseases:**

# Cyanosis

⚡ Cyanosis is caused by an increase in the deoxygenated haemoglobin level to above 5 g/dL

⚡ In all cyanotic heart lesions, the amount of cyanosis seen is dependent on the amount of pulmonary blood flow:

- Decreased PBF → increased cyanosis
- Increased PBF → minimal cyanosis but CHF may develop

⚡ A hyperoxia test is a test that is performed—usually on an infant—to determine whether the patient's cyanosis is due to lung disease or a problem with blood circulation (congenital heart disease).

- It is performed by measuring the arterial blood gases of the patient while they breathe room air, then re-measuring the blood gases after the patient has breathed 100% oxygen for 10 minutes.
- If the cause of the cyanosis is poor oxygen saturation by the lungs, allowing the patient to breathe 100% oxygen will augment the lungs' ability to saturate the blood with oxygen, and the partial pressure of oxygen in the arterial blood will rise (usually above 250 mmHg) → **PO<sub>2</sub> >250 is not congenital heart disease.**
- However, if the lungs are healthy and already fully saturating the blood that is delivered to them, then supplemental oxygen will have no effect, and the partial pressure of oxygen will usually remain below 100 mmHg. **PO<sub>2</sub> <100 is cardiac disease.**

⚡ Most common cyanotic lesions of the newborn (5 Ts)

- Tetralogy of Fallot
- Transposition of the Great Arteries
- Truncus Arteriosus
- Total Anomalous Venous Return
- Tricuspid Atresia

# Transposition of the Great Arteries



## INTRODUCTION

✦ **Complete transposition of the great arteries** is defined as: Aorta arises from the right ventricle; Pulmonary artery arises from the left ventricle.

- This results in complete separation of the 2 circuits; Hypoxemic blood circulating in the body, Hyperoxemic blood circulating in the pulmonary circuit.
- A Defect to permit mixing of 2 circulations is Necessary for survival: (ASD, VSD, PDA).
- VSD is present in 40% of cases

✦ It seen in 5% of all CHD

- Boys 3:1
- Most common cyanotic condition that requires hospitalization in the first two weeks of life.



## CLINICAL FEATURES

✦ Depend on anatomy present:

### 1. No mixing lesion and restrictive PFO:

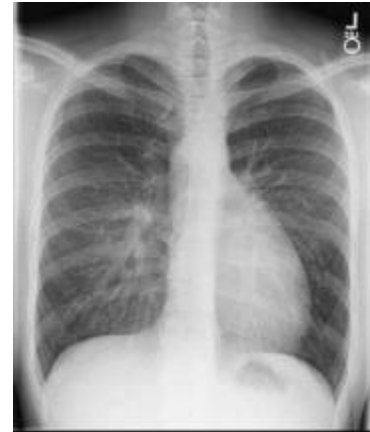- Profound hypoxia
- Rapid deterioration
- Death in first hours of life
- Absent respiratory symptoms or limited to
- Tachypnea
- Single second heart sound, no murmurs

### 2. Mixing lesion present (VSD or large PDA)

- Large vigorous infant
- Cyanotic
- Little to no resp distress
- Most likely to develop CHF in first 3-4 months of life: (excessive sweating (a cold, clammy sweat often noted during feeding); poor feeding, slow weight gain, irritability or lethargy, and/or rapid breathing.

✦ On chest X-ray:

- Egg shaped cardiac silhouette
- Narrow superior mediastinum



## TREATMENT

✦ Prostaglandin to establish patency of the ductus arteriosus:

- Increases shunting from aorta into the pulmonary artery
- Increases pulmonary venous return distending the left atrium
- Facilitates shunting from the left to the right atrium of fully saturated blood across the foramen ovale.

✦ Therapeutic balloon atrial septostomy (Rashkind Procedure) if surgery is not going to be performed immediately:

- Improves mixing and pulmonary venous return at the atrial level.

✦ Surgery consists of switching the right and left sided structures at the atrial level, at the ventricular level, or at the great artery level.

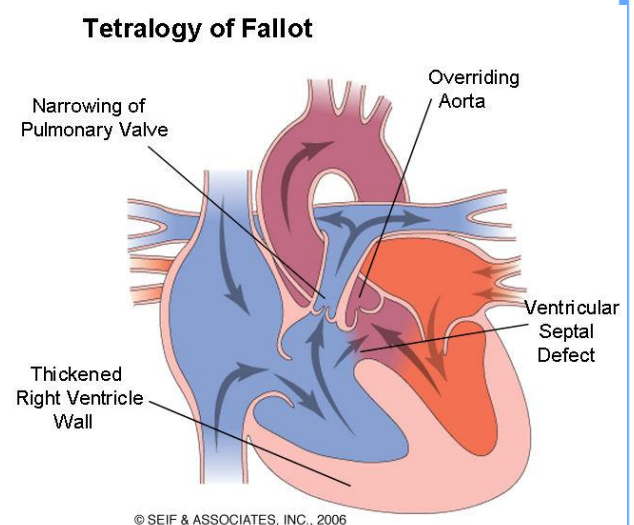
# Tetraology of Fallot



## INTRODUCTION

✦ It's the combination of 4 major congenital anomalies of the heart, the major problem in the embryogenesis here is the anterior & superior deviation of the outlet septum, that results in::

1. Non-restrictive malignant subarterial VSD.
2. Right ventricular outlet Obstruction (Sub valvular pulmonary stenosis)
3. Right ventricular hypertrophy
4. Overriding aorta







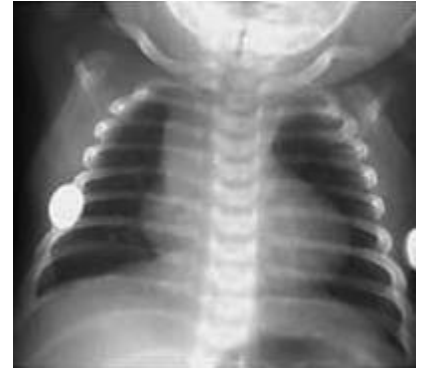## CLINICAL FEATURES

⚡ **Symptoms:** Cyanosis, clubbing, dyspnea on exertion, squatting, hypoxic spells.

⚡ **Signs:** Loud systolic ejection murmur, systolic thrill at middle LSB.

- Soft murmurs are associated with less blood flow and more hypoxia

⚡ Boot shaped heart on the X-ray.



## TREATMENT

⚡ Early surgical repair depends on the patient's weight.

- VSD is closed and obstructing ventricular muscle is removed.

⚡ TET Spell Treatment: (the goal is to increase SVR or decrease PVR)

- Hold infant in knee-chest position to increase SVR (toddlers or older children's may insensitively Squat when they are short of breath).
- Oxygen supply
- Fluid bolus (increase SVR)
- Morphine (decrease agitation).
- Sodium bicarbonate to treat acidosis
- Vasoconstrictor (phenylephrine)
- Propranolol

### Hypoxic Spell (TET spell)

⚡ Peak incidence of 2-4 months

⚡ Characterized by:

1. Hyperapnea (Rapid and deep respirations)
2. Irritability and prolonged crying
3. Inc cyanosis
4. Decreased heart murmur

⚡ Pathophysiology:

- Lower SVR or increase resistance of RVOT can increase the R-L shunt:
- Stimulates the respiratory center to produce hyperapnea.
- Results in an increase in systemic venous return
- In turn, increases R-L shunt through VSD

# Total Anomalous Pulmonary Venous Return



## INTRODUCTION

✦ The pulmonary veins drain into the RA or its venous tributaries rather than the LA

- An interatrial communication (ASD or PFO) is necessary for survival. Pulmonary venous return reaches the RA.
- Systemic and pulmonary venous blood are completely mixed.

✦ Types:

1. **Supracardiac:** Common pulmonary vein drains into the SVC via the left SVC and left innominate vein.
2. **Cardiac:** The common PV drains into the coronary sinus.
3. **Infracardiac:** the common PV drains into the portal vein, ductus venosus, hepatic vein, or IVC.
4. **Mixed:** a combination of the other types.



## CLINICAL FEATURES

✦ Clinical Signs for Unobstructed Veins:

- Mild cyanosis, signs of CHF in infancy, history of pneumonia.
- Widely split S2, Grade 2-3/6 systolic murmur heard at the ULSB
- CXR- marked cardiomegaly.

✦ Clinical Signs for Obstructed Veins

- Profound desaturation
- Acidosis
- PGE1 administration does not improve oxygenation because elevated pulmonary pressures in the right side of the heart (due to obstructed pulmonary outflow) will result in right to left shunting across an open ductus further decreasing arterial saturation.



## TREATMENT

- ⌘ Digitalis and diuretics to treat heart failure
- ⌘ Intubation and inc PEEP for those with severe pulm over load
- ⌘ Corrective surgery.

# Tricuspid Atresia



## INTRODUCTION

- ⌘ Tricuspid valve is absent
  - RV and PA are hypoplastic.
  - Associated defects- ASD, VSD, or PDA (necessary for survival)
  - Dilation of LA and LV
  - Essentially single ventricle physiology.



## CLINICAL FEATURES

- ⌘ **Symptoms:** Severe cyanosis, poor feeding, tachypnea.
- ⌘ **Signs:** Single S2, grade 3/6 systolic murmur at LLSB if VSD is present
- ⌘ CXR- boot shaped heart.



## TREATMENT

- ⌘ PGE IV infusion
- ⌘ **Blalock-Taussig shunt** in infancy
  - systemic to pulmonary arterial shunt
  - Provide stable blood flow to the lungs
  - A gortex tube is sewen between the subclavian artery and the right pulmonary artery.
- ⌘ **Bidirectional Glenn**
  - Superior vena cava is connected to the pulmonary arteries
  - IVC continues to be connected to the heart
- ⌘ **Fontan Procedure:** Redirects IVC to lungs.

# Truncus Arteriosus



## INTRODUCTION

✚ A single trunk leaves the heart Gives rise to pulm, systemic, and coronary circulations:

- Large VSD is always present



## CLINICAL FEATURES

✚ Cyanosis immediately after birth

✚ Early signs of CHF

✚ 2-4/6 systolic murmur at LSB suggestive of VSD



## TREATMENT

✚ Anticongestive medications (diuretics and digitalis)

✚ Corrective surgery

- VSD is closed
- Pulmonary artery is separated from the truncus
- Continuity is then established between the right ventricle and the pulmonary artery utilizing a valved homograft conduit



# Vascular surgery

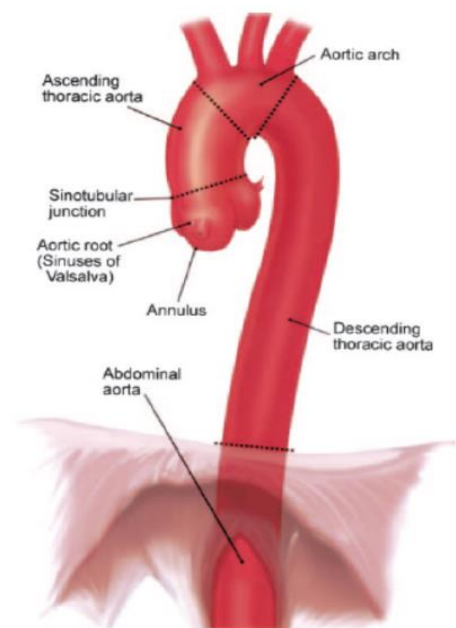
- Aortic disease: page 104
  - Written by: Bushra Arafa Zayed.
- Abdominal aortic aneurysm: page 112
  - Written by: Aya Qteish
  - Corrected by: Ayat M. Zghoul
- Peripheral arterial disease: Page 119
  - Written by: Bushra Arafa Zayed.
  - Corrected by: Aya Qteish
- Peripheral vascular injury: page 127
  - Written by: Mohammad Qussay Al-Sabbagh
- Peripheral Venous disease: page 135
  - Written by: فاعل خير.
  - Corrected by: Bushra Arafa Zayed.
- Arterial & venous ulcers: page 141
  - Written by: Majd Al Rawashdeh
- Central venous lines & AV shunts: page 143
  - Written by: Mohammad Qussay Al-Sabbagh

# Aortic diseases

## Thoracic Aortic dissection

### INTRODUCTION

- Aneurysm and dissection are the most common diseases of the aorta.
- **Definition of dissection:** Tear in the intima of the aorta resulting in blood leaving the normal aortic channel and dissecting through the media producing a false channel.
- Typically occurs in 50-70 year old men with Hypertension and those with connective tissue disorder.
- Thoracic aorta anatomy:
  - Ascending aortic aneurysms occur as proximally as the aortic annulus and as distally as the innominate artery.
  - Transverse aortic arch: brachiocephalic branches.
  - Descending thoracic aorta: distal to left subclavian artery until the diaphragmatic hiatus. From this segment, multiple bronchial and esophageal branches as well as the segmental intercostal arteries, which provide circulation to the spinal cord, arise.

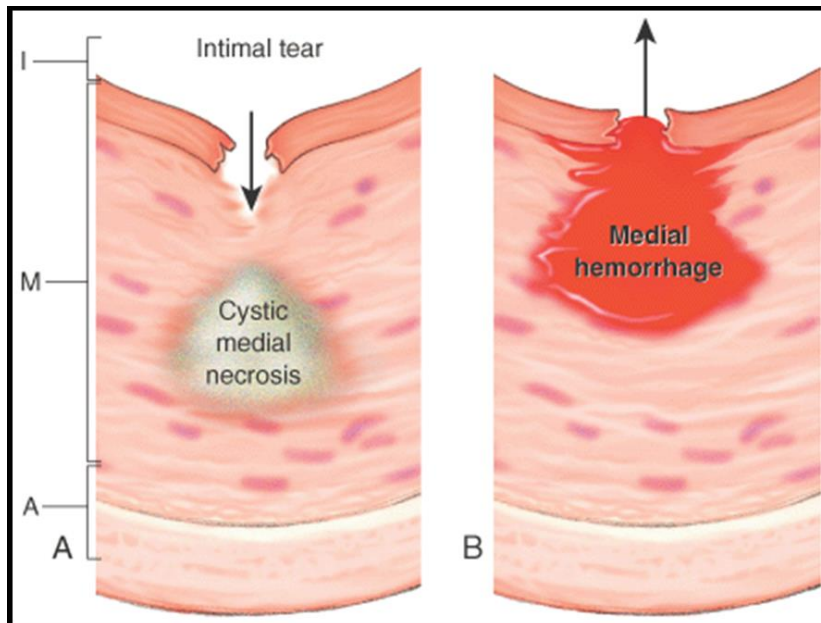


### PATHOPHYSIOLOGY

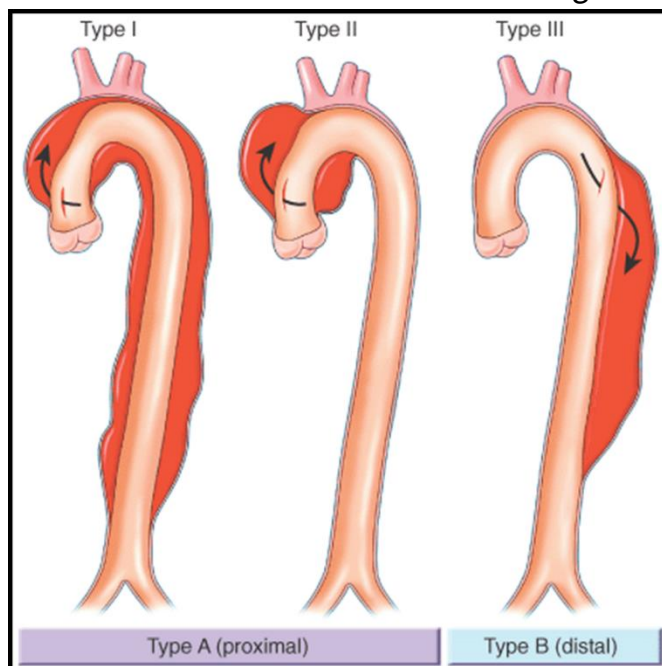
- True and false lumens are separated by intimal flap. Fenestrations in intimal flap produces flow in both lumens -double barrel aorta- and possible compromised flow to branches of aorta (organs and extremities) may result. False lumen weakens with time causing aneurysm or rupture.



- The following picture summarizes the proposed mechanism of initiation of aortic dissection:



- Aortic dissection is classified according to the site as follows:





## CLINICAL FEATURES

### ➤ Signs and Symptoms:

The patient may have:

1. Severe pain (90%): tearing, inter-scapular, precordial or neck pain.
  2. Aortic Murmur: dissection causing incompetence.
  3. Cardiac Tamponade : rupture into pericardium
  4. Or Signs of occlusion of major branch vessels:
    - Coronary - hypotension and chest pain
    - Arch - stroke - rarely improves with restoration of flow
    - Intercostal - paraplegia
    - Renal - oliguria, anuria
    - Visceral - acute abdomen
    - Iliac - ischemic leg , pulse deficit.
- 
- ### ➤ Complications:
- Hemorrhage.
  - Myocardial infarction.
  - Stroke.
  - Visceral necrosis.
  - Renal failure.
  - Death.



## DIAGNOSIS

1. History, Physical.
2. Investigations:
  - ◆ Chest X-ray: widened mediastinum, cardiomegaly, and pleural effusion. *See figure A.*
  - ◆ Aorto-gram. *See figure B.*
  - ◆ Trans-esophageal ECHO.
  - ◆ 2-D ECHO: identifies intimal flap/false channel, noninvasive, no contrast media, bedside.

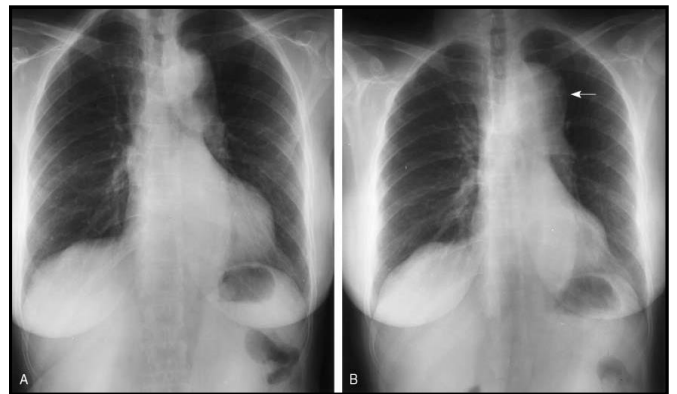


Figure A

- ◆ CT scan: identifies intimal flap rapidly, requires contrast media, and identifies rupture.
- ◆ Digital Subtraction Angio.



## TREATMENT

### ➤ Medical:

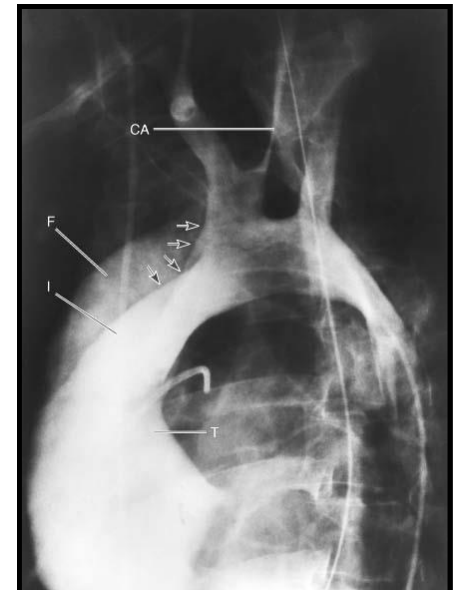
In Uncomplicated Type B;

- ◆ Control pain.
- ◆ Control BP.

### ➤ Surgical:

- ◆ In all Type I, II (Type A) and complicated type III (Type B) dissections (i.e. leak, limb or gut ischemia, acute renal failure, paraparesis, uncontrolled pain).
- ◆ NOTE: In surgery, you need to consider the conditions of the patient such as; advanced age, limiting comorbidities, +/- paraplegia.

Figure B



*NOTE: Digital subtraction angiography (DSA) is a fluoroscopy technique used in interventional radiology to clearly visualize blood vessels in a bony or dense soft tissue environment.*

# Thoracic Aortic Aneurysm -TAA-



## INTRODUCTION

**Definition:** localized or diffuse aortic dilation that exceeds 50% of the normal aortic diameter.



## ETIOLOGY

- Risk factors:
  - Advanced age.
  - Hypertension.
  - Diabetes.
  - Smoking.
  - Bicuspid aortic valve.
  - Connective tissue disorders ( ex: Marfan's).
  - Infections.
  - Trauma.
  - Male Gender.
  - Family History.



## PATHOPHYSIOLOGY

- It results from degenerative changes in the wall of the aorta, which lead to cystic medial necrosis. This causes damage to collagen and elastin, loss of smooth muscle cells, and increased amounts of basophilic ground substance in the medial (elastic) layer of the aorta. The ascending thoracic aorta is generally most affected by cystic medial necrosis.
- Atherosclerosis is coexisting process rather than the underlying cause.
- TAAs are subdivided into the following three groups depending on location:
  - Ascending aortic aneurysms.
  - Aortic arch aneurysms.
  - Descending thoracic aneurysms or thoraco-abdominal aneurysms.

- Aortic diameter was a strong predictor of rupture, dissection, and mortality.
- Critical diameters: 6.0 cm ascending aorta and 7.0 cm descending aorta.



## CLINICAL FEATURES

### Signs and Symptoms:

patient may present with one of the following:

- ◆ Asymptomatic
- ◆ Pain ; which implies sudden extension or rupture of aneurysm; and the site of the pain is according to the segment of the aorta involved:
  - Ascending aorta - neck, jaw
  - Descending aorta - back, inter-scapular
  - Thoracoabdominal aorta - low back
- ◆ Compression of adjacent structures.
  - SVC syndrome.
  - Hoarseness, laryngeal nerve compression.
- ◆ Erosion into the surrounding structures; GI, RS.
- ◆ Aortic Valve Insufficiency.
- ◆ Distal Embolization.
- ◆ Rupture.



## DIAGNOSIS

- ◆ History and physical exam.
- ◆ Investigations:
  - Plain Radiographs; may show one of the following findings, *see figure 3*:
    - Convexity in the right superior mediastinum
    - Loss of the retrosternal space.

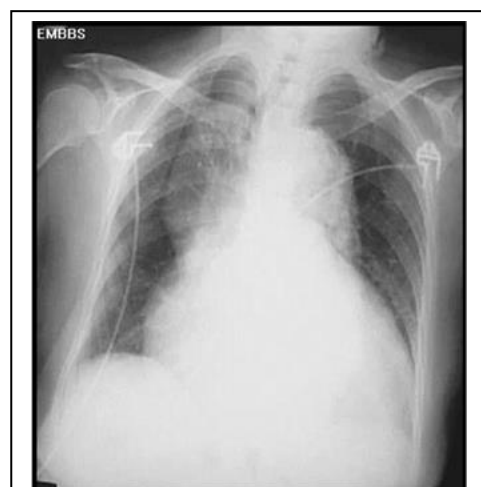


Figure 3

→ Widening of the descending thoracic aortic shadow (calcification).

- ECHO.
- CT scan; see figure 4.
- MR Angio.
- Aortogram and Cardiac catheterization.

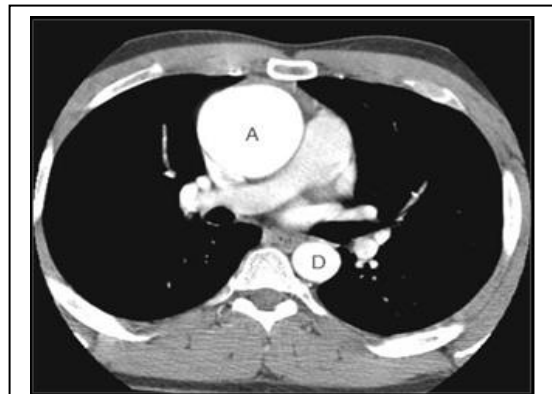


Figure 4



## TREATMENT

### ➤ Medical:

- Life Style Modification.
- Smoking Cessation.
- BP Control.
- Beta-blockade with Propanolol.
- Periodic Exams, such as periodic CTs if close to surgical threshold.

### ➤ Surgical:

#### ❖ Indication for surgery:

##### 1- Ascending:

- Acute or Chronic Dissection.
- Rupture.
- Progressive enlargement.
- Marfan's pt. with size > 5 cm.
- More than 6cm.

##### 2- Arch:

- All symptomatic patients.
- 5-6 cm fusiform aneurysms.
- All pseudo-aneurysms.

##### 3- Descending/ Thoracoabdominal:

- All symptomatic patients
- Twice the normal size of the aorta or 6 cm.
- Progressive enlargement (> 1 cm/yr)

#### *Remember*

- ♦ *Pseudo-aneurysm: is a breach in the vascular wall leading to an extravascular hematoma that freely communicates with the intravascular space.*

#### *While*

- ♦ *True aneurysm is, as mentioned, abnormal dilatation of the aorta involving the three layers of the artery.*

## ❖ Types of surgery:

### ➤ **Ascending aorta:**

- If there are healthy aortic valve, annulus, and sinuses of Valsalva → simple dacron graft.
- If the valve is, also diseased → Bentall procedure is the choice.

*Bentall procedure: cardiac surgery operation involving composite graft replacement of the aortic valve, aortic root and ascending aorta, with re-implantation of the coronary arteries into the graft.*

### ➤ **Aortic arch aneurysms:**

- Deep hypothermic circulatory arrest (DHCA) with or without antegrade or retrograde cerebral perfusion is usually used to facilitate reanastomosis of the arch vessels. Aortic arch reconstruction techniques vary, depending on the arch pathology.
- Surgical options:
  - ◆ Hemi arch replacement.
  - ◆ Total arch replacement.
  - ◆ Trifurcated head-vessel attachment graft.

### ➤ **Descending aortic aneurysms:**

- Either open or endovascular repair.
- With or without the use of a bypass circuit.
- Thoracoabdominal aneurysms may be repaired with the use of a partial bypass of the left atrial artery to the femoral artery.
- Prevention of paraplegia is one of the principal concerns.

## ❖ Surgical complications:

- ◆ Bleeding.
- ◆ Stroke (in arch repair) due to hypothermic circulatory arrest.
- ◆ Myocardial infarction.
- ◆ Pulmonary dysfunction.
- ◆ Renal dysfunction.
- ◆ Paraparesis and paraplegia.
- ◆ Specific Endovascular stenting complications : endoleaks, stent fractures, and stent graft migration.



# Abdominal Aortic Aneurysm (AAA)

(The most common type of aneurysms)

## **Anatomy:**

- Abdominal aorta begins at T12 and ends at L4. Aorta bifurcates at the level of umbilicus (L4); therefore, when palpating for an AAA, palpate above the umbilicus and below xiphoid process.
- 2 cm in diameter, 15 cm long (It's longer in tall people, men and athletes).
- Branches of abdominal aorta:
  1. Anterior branches (single branches): celiac trunk, SMA, IMA, median sacral artery.
  2. Paired branches: suprarenal arteries, renal arteries, gonadal arteries, lumbar arteries.
  3. Terminal branches: iliac arteries.
- Relationships:
  - Anteriorly: pancreas, left renal vein and ascending part of duodenum.
  - Posteriorly: upper 4 lumbar vertebrae.
  - On the right: IVC
  - On the left: left sympathetic trunk.

## **Histology:**

- The three layers of arterial wall: intima, media, adventitia.
- True aneurysm: dilation of all three layers.
- False aneurysm: dilation of artery not involving all three layers (e.g., hematoma with fibrous covering). Often connects with vessel lumen and blood swirls inside the false aneurysm.

# AAAs



## **INTRODUCTION**

**Definition:** focal dilation of the abdominal aorta ( $>1.5\times$  normal diameter 2cm  $\rightarrow$   $>3$ cm).

Arteriomegaly: diffuse (non-focal) enlargement of several arterial segments.

## **Epidemiology:**

- Incidence: 5% of all adults older than 60 years of age.
- Male to female ratio 6:1 (white males are at the highest risk)

## Notes:

- The most common site is infrarenal (95%).
- 20% of patients with AAA have a peripheral arterial aneurysm.
- AAAs grow 3 mm/year on average (larger AAAs grow faster than smaller AAAs).

## ? ETIOLOGY

### Risk factors:

**Atherosclerosis** in 95% of cases (**most common**), HTN, smoking, male gender, advanced age, connective tissue diseases (e.g. *ehlers danlos syndrome*), Mycotic, genetic predisposition (family Hx is important).

The term 'mycotic' is a misnomer because most result from bacteria (like *Chlamydia*) not fungi.

## ⚡ PATHOPHYSIOLOGY

Pathogenesis is complex and multifactorial

### Visible hallmarks:

1. Inflammation → breakdown of elastic elements → ↓ tensile strength → leading to expansion.
2. Smooth muscle cells apoptosis.
3. ECM degeneration.

### Classification:

- Wall** (true, false)
- Morphology** (fusiform, saccular)
- Aetiology** (atheromatous, mycotic, collagen diseases, traumatic)

## 🔍 CLINICAL FEATURES

- Most AAAs are **asymptomatic** and discovered during routine abdominal exam by primary care physicians.
- If symptomatic → vague epigastric discomfort with back and flank pain due to vertebral compression. Pain may also occur in the thigh and groin because of nerve compression.

### Complications:

1. Rupture (see later)

2. Arterio-aortic embolism: mural thrombus within the aneurysm can detach and cause distal emboli (Blue toe syndrome, characterized by purple discoloration of toes and forefoot of both feet. There is usually a full set of pedal pulses).



## DIAGNOSIS

-**Labs:** CBC, electrolytes, LFTs, coagulation tests and blood lipid estimation.

-**Imaging:**

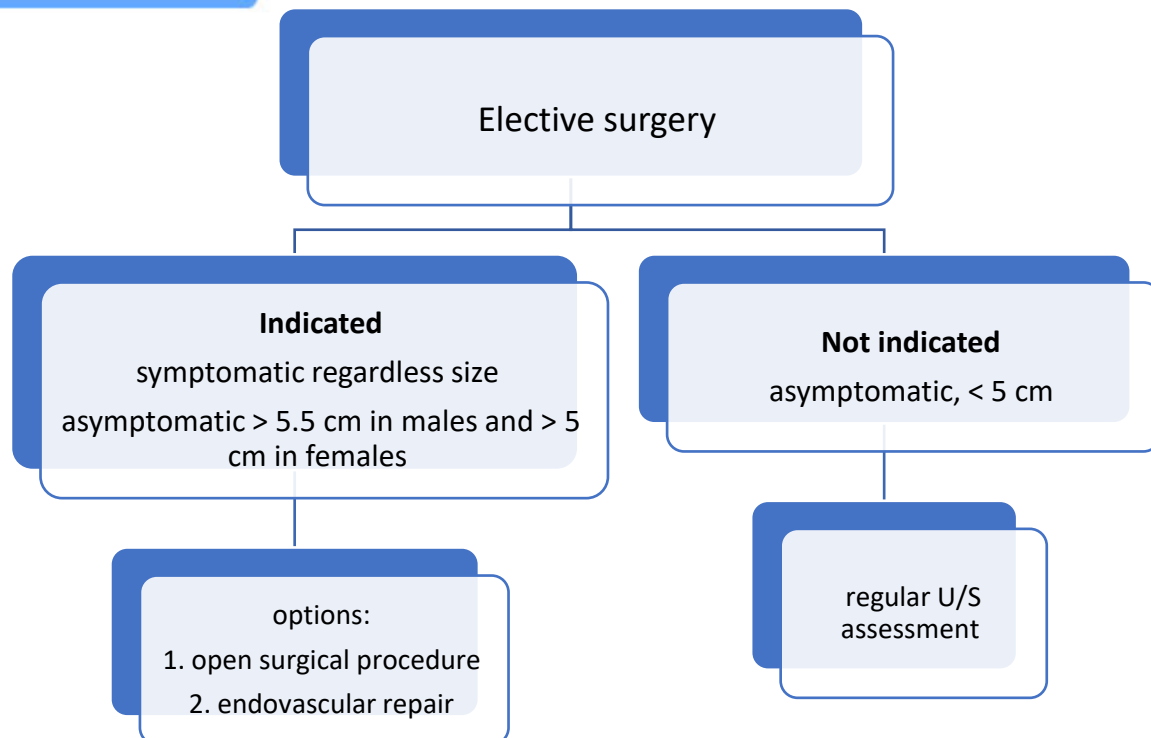
1. U/S (screening test of choice to document or to rule out the presence of aneurysm)
2. CT-scan (the morphology of aneurysm is best assessed by CT)
3. AXR (signs of AAA: calcification in the aneurysm wall, best seen on lateral projection a.k.a eggshell calcification)
4. A-gram (assesses lumen patency and iliac/renal involvement.

- Limitation of A-gram: AAAs often have large mural thrombi, which result in a falsely reduced diameter because only the patent lumen is visualized.

-**Differential Dx:** renal colic (most common misdiagnosis of AAA, so if a patient presented with new onset of renal colic at age of 50 and above you should think about AAA). Others: acute pancreatitis, aortic dissection, mesenteric ischemia, MI, perforated ulcer, diverticulosis.



## TREATMENT



**1. Open surgical procedure:** prosthetic graft placement, with rewrapping of the native aneurysm adventitia around the prosthetic graft after the thrombus is removed; when rupture is strongly suspected, proceed to immediate laparotomy; there is no time for diagnostic tests!

-Why wrap the graft in the native aorta?

To reduce the incidence of enterograft fistula formation.

-What type of repair should be performed with AAA and iliacs severely occluded or iliac aneurysm(s)?

Aortobi-iliac or aortobifemoral graft replacement (bifurcated graft)

**-complications:**

1. Cardiac (ischemia and infarction) }

2. Respiratory (atelectasis and lower lobe consolidation) }

most common

3. Colonic ischemia (usually is seen in the first week postoperatively)

4. Aortoenteric fistula (fistula between aorta and duodenum) → long term complication that often presents with both upper and lower GI bleeding.

5. anterior spinal syndrome.

Others: atheroembolism, declamping hypotension, acute renal failure (especially if aneurysm involves the renal arteries), ureteral injury, hemorrhage, graft infection, aortovenous fistula (to IVC), erectile dysfunction (sympathetic plexus injury), retrograde ejaculation.

-Why is colonic ischemia a concern in the repair of AAAs? Often the IMA is sacrificed during surgery; if the collaterals are not adequate, the patient will have colonic ischemia.

-Signs of colonic ischemia: Heme-positive stool, or bright red blood per rectum (BRBPR), diarrhea, abdominal pain.

-The study of choice to diagnose colonic ischemia is colonoscopy

-Treatment of necrotic sigmoid colon from colonic ischemia: 1. Resection of necrotic colon

Anterior spinal syndrome : 1. Paraplegia 2. Loss of bladder/bowel iliac/renal control 3. Loss of pain/temperature sensation below level of involvement 4. Sparing of proprioception

-Which artery is involved in anterior spinal syndrome? Artery of **Adamkiewicz**- supplies the anterior spinal cord .

-The most common bacteria involved in aortic graft infections: 1. Staphylococcus aureus. 2. Staphylococcus epidermidis(usually late)

- How is a graft infection with an aortoenteric fistula treated? Perform an **extra-anatomic bypass** with resection of the graft

-Extra-anatomic bypass graft: Axillofemoral bypass graft- **graft not in a normal vascular path**;usually, the graft goes from the axillary artery to the femoral artery and then from one femoral artery to the other ( fem-fem bypass ).

**2. Endovascular aneurysm repair (EVAR):** placement of a stent proximal and distal to an AAA through a distant percutaneous access (usually through the groin).

**-Advantages:**

1. Has reduced mortality compared to open repair over the first six years.
2. Less invasive and less hospital stay.
3. Less cardiac, respiratory, renal and neurological complications.

**-Disadvantages:**

1. Expensive
2. Patients require life-long follow up and surveillance with duplex or CT scans to detect endoleak, disconnection of the components and migration of the stent graft, all of which predispose to late rupture.

**-Causes of unsuitability:** short, flared or angulated neck and difficult iliac artery access because of narrowing or tortuosity.

**NOTE:** 50% of infrarenal aneurysms are suitable for EVAR which is dependent on the morphology of the aneurysm when assessed by CT scan.

Mortality rate associated with elective surgery is <4% (GOOD)

## Ruptured Abdominal Aortic Aneurysm



### INTRODUCTION

**Definition:** disruption of dilated aortic wall that leads to blood outside it.

**Epidemiology:**

- Risk of rupture is higher in female.
- Less than 50% of patients with rupture survive to reach hospital.

## ? ETIOLOGY

**Risk factors:** hypertension, smoking, COPD, increasing aneurysm diameter, recent rapid expansion, large diameter, symptomatic

### NOTES:

- Risk of rupture per year based on AAA diameter size :

<5.5 cm → rupture risk 1-2%

5.5 – 6.5 cm → 8%

8 cm → 25%

10cm → 100%

-Why do larger AAAs rupture more often and grow faster than smaller AAAs?

Because of Laplace's law (wall tension= pressure × diameter)

## ⚡ PATHOPHYSIOLOGY

### Types:

1. **Intra-peritoneal rupture (20%)** → free bleeding into peritoneal cavity → very few patients reach hospital alive.

2. **Retro-peritoneal rupture(80%)** →retroperitoneal hematoma →extreme emergency

## 🔍 CLINICAL FEATURES

### Classic triad of ruptured AAA :

1. Abdominal pain.

2. Pulsatile abdominal mass

3. Hypotension

-What do testicular pain and AAA signify?

Retroperitoneal rupture with ureteral stretch and referred pain to the testicle.





## DIAGNOSIS

### Investigations:

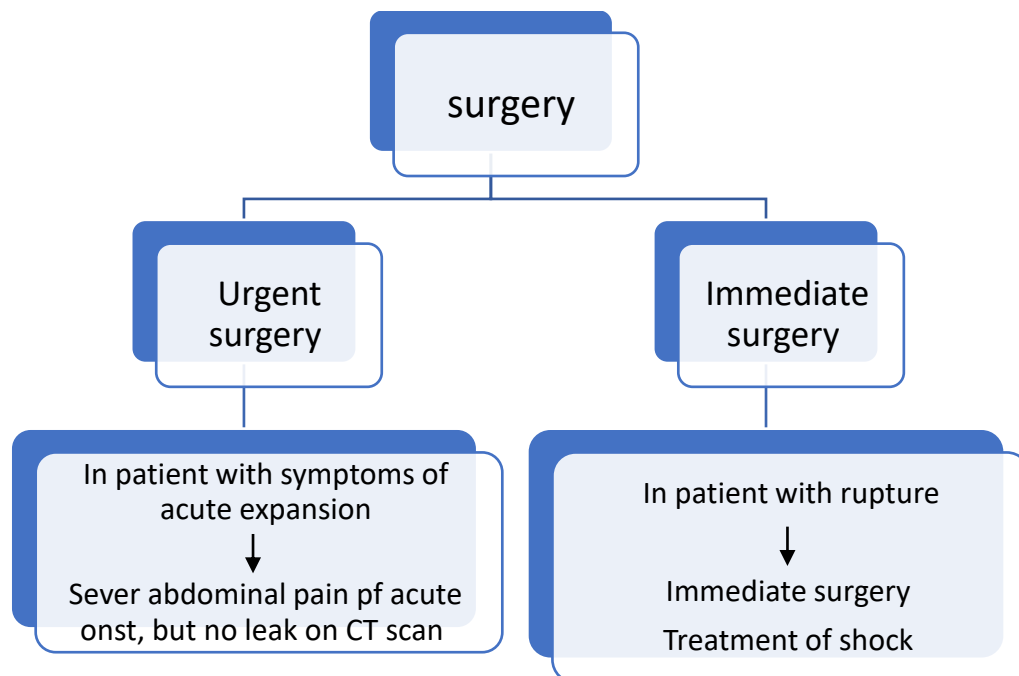
- CT scan is the investigation of choice
- U/S → can't be used to diagnose rupture.



## TREATMENT

### Management of ruptured abdominal aortic aneurysm:

- Early diagnosis (abdominal/back pain, pulsatile mass, shock)
- Immediate resuscitation (oxygen, intravenous replacement therapy, central line)
- Maintain systolic pressure, but not > 100 mmHg, consider permissive hypotension where fluids are withheld if the patient is conscious (and cerebral perfusion is therefore adequate), in order to avoid provoking further uncontrolled hemorrhage.
- Urinary catheter
- Cross match six units of blood (If the patient appears stable)
- Rapid transfer to the operating theatre.



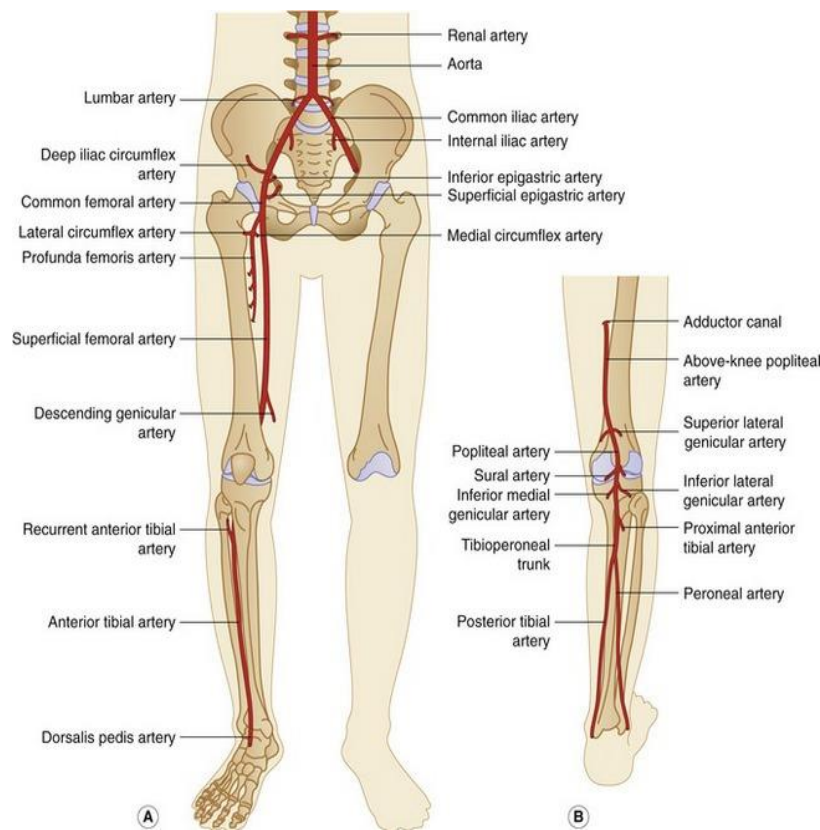
**Mortality rate associated with immediate surgery for ruptured aneurysm is 50%**

# PERIPHERAL ARTERIAL DISEASE -CHRONIC-

## INTRODUCTION

### ❖ Lower limb arterial anatomy:

Starting at the abdominal aorta, the abdominal aorta splits into common iliac arteries; right and left→The common iliac arteries then divide into the internal and external branches → the external iliac artery becomes the common femoral artery as it crosses under the inguinal ligament to enter the femoral triangle→The common femoral artery then gives off a deep branch known as the profunda femoris artery, this is also known as the deep femoral artery and the femoral artery then continues as the superficial femoral artery → passes into the posterior compartment of the leg becoming the popliteal artery →which divides into anterior and posterior tibial arteries→posterior tibial artery gives off a fibular artery, which is referred to sometimes as the peroneal artery, the anterior tibial artery becomes the dorsalis pedis artery.



❖ **Definition:**

Peripheral artery disease (PAD) is defined as a clinical disorder in which there is a stenosis or occlusion in the aorta or the arteries of the limbs.

❖ **Epidemiology:**

Arterial disorders represent the most common cause of morbidity and death in Western societies. Much of this is due to the effects of atheroma on the arteries.

The highest prevalence of atherosclerotic PAD occurs in the sixth and seventh decades of life.

## ? **ETIOLOGY**

Arterial stenosis or occlusion is commonly caused by atheroma.

Other causes include thrombosis, embolism, vasculitis, fibromuscular dysplasia entrapment, cystic adventitial disease, and trauma.

Risk factors:

- Smoking.
- Hypertension.
- Diabetes mellitus.
- Hyperlipidemia

## ⚡ **PATHOPHYSIOLOGY**

- Features of **chronic** arterial stenosis or occlusion in the **leg**:

1- **Intermittent claudication:**

→ Intermittent claudication is a cramp-like pain felt in the muscles that is:

- brought on by walking;
- Not present on taking the first step (unlike osteoarthritis)
- relieved by standing still (unlike pain of nerve compression).

- Claudication happens after walking a certain distance “claudication distance”. This distance is used to estimate the degree of occlusion, so as the distance decreases; a higher degree of occlusion is present.
- The pain of claudication is usually felt in the calf because the superficial femoral artery is the most commonly affected (70%). Aorto-iliac disease (30% per cent of cases) may cause thigh or buttock claudication.
- Buttock claudication in association with sexual impotence resulting from arterial insufficiency is called **Leriche's syndrome**. -RARE-

## 2- Rest pain:

- Rest pain occurs with the limb at rest, is felt in the foot and is exacerbated by lying down or elevation of the foot. Characteristically, the pain is worse at night and it may be lessened by hanging the foot out of bed or by sleeping in a chair.

## 3- Ulceration and gangrene:

- **Ulceration** occurs with severe arterial insufficiency and may present as a painful erosion between the toes or as shallow, non-healing ulcers on the dorsum of the feet, on the shins and especially around the malleoli.
- **Gangrene** refers to death of macroscopic portions of tissue, which turn black because of the breakdown of hemoglobin and the formation of iron sulphide. It usually affects the most distal part of a limb because of arterial obstruction (from thrombosis, embolus or arteritis).
  - Dry gangrene occurs when the tissues are desiccated by gradual slowing of the bloodstream ("mummified tissue"); it is typically the result of atheromatous occlusion of arteries. Wet gangrene occurs when superadded infection and putrefaction are present. A zone of demarcation between the truly viable and the dead or dying tissue will eventually appear.
  - Separation is achieved by the development of a layer of granulation tissue, which forms between the dead and the living parts. Moreover, usually this line is better visualized and located more distally in case of dry gangrene unlike the wet gangrene.
- They (i.e. ulceration and gangrene) are usually seen when there is a multi-level disease.



## CLINICAL FEATURES

### Signs and Symptoms:

- The severity of the symptoms is related to the size of the vessel occluded and whether the stenosis or occlusion occurs suddenly (acute) in a previously normal artery or gradually (chronic) with progressive narrowing of the artery over time as in chronic arterial narrowing, a collateral circulation may develop and provide an alternative route for blood flow which reduces symptoms until a critical stenosis or occlusion has developed.
- And according to what was explained previously, the patient may have one of the features of chronic arterial stenosis of the leg:
  - 1- Intermittent claudication.
  - 2- Rest pain.
  - 3- Ulceration
  - 4- Gangrene.

- **Upon physical exam, you might notice:**

-Pale limbs, and this pallor becomes obvious when elevating the limb -burger's test-

- Muscle atrophy.

-thin shiny hairless skin.

- Constriction of the base of the toes.

- Nail thickening.

- guttering of the veins.

*By inspection.*

-Delayed capillary refill -around 10 seconds instead of 2-3 seconds-.

-cold limbs.

- edema.

-pulses: reduced pulses distal to the stenosis and you may hear a bruit; however these are not reliable signs.

*By palpation*

**History:** the patient usually presents with one of the mentioned features of chronic arterial stenosis

**Physical exam:** mentioned above.

**Investigations:**

- 1- Doppler ultrasound blood flow detection: a normal artery has a triphasic signal that can be detected by a trained observer. However, although the presence of a Doppler signal indicates moving blood, it does not necessarily indicate that the blood flow is sufficient to maintain limb viability and prevent limb loss.

In addition, Doppler is used to measure the **ankle-brachial index** -ABPI-: resting ABPI is normally about 1.0; values below 0.9 indicate some degree of arterial obstruction (claudication), less than 0.5 suggests rest pain and less than 0.3 indicates imminent necrosis. However this ratio might be deceiving.

- 2- Duplex scanning: which allows a detailed visualization of the blood flow within the vessels.
- 3- Angiography: invasive technique.

Tri-phasic waveform on U/S:  
-forward flow in systole  
-reverse flow in late systole / early diastole  
-forward flow in late diastole



## TREATMENT

**General:** smoking cessation, exercise, dietary and weight reduction are usually useful in those with claudication as they induce collateral circulation formation and reduce the risk for progression into critical limb ischemia.

**Medical:**

- Drugs to control diseases associated with arterial disorders, such as hypertension and diabetes
- Statins should be used even if the lipid profile is normal.
- Aspirin -or clopidogrel if aspirin cannot be used-.

**NOTE:** Beta-blockers exacerbate claudication.

**Surgical:**

1. Transluminal angioplasty and stenting:

→ Arterial occlusive disease may be treated by inserting a balloon catheter into an artery and inflating it within a narrowed or blocked area. This technique is suitable for patients with claudication, rest pain or tissue necrosis. It has proved very successful in dilating the iliac and femoropopliteal segments; the results below the knee are less successful. Complications include (5%):

- ❖ Failure.
- ❖ Hematoma.
- ❖ Bleeding.
- ❖ Thrombosis.
- ❖ Distal embolization.

→ In case that the artery cannot be held open by balloon only, a stent may be placed.

## 2. Bypass surgery:

→ Usually reserved for patients with severe symptoms where angioplasty has failed or is not possible. And the exact technique of bypass depends on the site and the degree of occlusion.

→ Autogenous saphenous vein gives the best results.

- Long-term graft patency is determined by the quality of inflow and outflow, graft length(whether the distal anastomosis is above or below the knee) and the conduit used for the bypass.
- NOTE: in the case of claudication we start with general and medical treatment, we go for surgery in severe claudication refractory to conservative treatment.
- NOTE: Isolated common femoral artery or profunda disease can be treated with endarterectomy and patch (vein or prosthetic) or a short bypass in the groin.
- NOTE: Arterial stenosis can occur in vessels other than the lower extremities' vessels, and the symptoms are differ according to the artery occluded:
  - 1- Carotid artery stenosis: may cause transient ischemic attacks (TIA). These short-lived mini-strokes are often recurrent and cause unilateral motor or sensory loss in the arm, leg or face, transient blindness (amaurosis fugax) or speech impairment. Patients should be assessed with a duplex scan. If a tight stenosis (>70 per cent) is detected, carotid endarterectomy should be offered.
  - 2- Subclavian artery stenosis may cause claudication in the arm or digital ischemia from distal embolization.



- 3- Mesenteric artery occlusive disease may cause pain after eating (intestinal angina) and weight loss. In general, two of the three mesenteric vessels should be occluded to produce symptoms.
- 4- Renal artery stenosis may cause hypertension and eventual renal failure. The mainstay of treatment is drugs to control hypertension, diabetes, etc.

## PREPHERIAL ARTERIAL DISEASE -ACUTE-

### ? ETIOLOGY

Acute limb ischemia results from sudden occlusion of an artery supplying the limb. this occlusion is usually caused by an embolus.

Sources of this embolus include

- The left atrium in atrial fibrillation.
- left ventricular mural thrombus following myocardial infarction
- Vegetations on heart valves in infective endocarditis.
- Thrombi in aneurysms
- Atherosclerotic plaques.

NOTE: Emboli may lodge in any organ and cause ischemic symptoms.

### 🔍 CLINICAL FEATURES

Discussion here will be mainly on acute limb ischemia.

#### Signs and Symptoms: (6 P's)

- Pallor
- Pulseless
- Perishing cold
- Paresthesia
- Paralysis
- Pain on squeezing the muscle

## Complications:

- 1- Limb loss: Embolic arterial occlusion is an emergency that requires immediate treatment. Ischemia beyond 6 hours is usually irreversible and results in limb loss.
- 2- Compartment syndrome: In limbs that have been subjected to sudden ischemia followed by revascularization, edema is likely. Muscles swell within fixed fascial compartments and this can itself be a cause of ischemia. And the treatment is fasciotomy.



## DIAGNOSIS

The diagnosis can be made clinically in a patient who has no history of claudication and has a source of emboli, who suddenly develops severe pain or numbness of the limb, which becomes cold and mottled.



## TREATMENT

- 1- Because of the ensuing stasis, a thrombus can extend distally and proximally to the embolus. The immediate administration of heparin intravenously can reduce this extension and maintain patency of the surrounding (particularly the distal) vessels until the embolus can be treated.
- 2- The relief of pain is essential because it is severe and constant.
- 3- Embolectomy.
- 4- Thrombolysis: when ? If ischemia is not so severe that immediate operation is essential, it may be possible to treat either embolus or thrombosis by intra-arterial thrombolysis. HOWEVER, it is contraindicated in the following cases: recent stroke, bleeding diathesis and pregnancy, and results in those over 80 years old are poor.

**\*Remember acute limb ischemia is an emergency case.\***

# Peripheral vascular Injuries

## INTRODUCTION

⚡ **Peripheral vascular injuries** may result from penetrating or blunt trauma to the extremities. If not recognized and treated rapidly, injuries to major arteries, veins, and nerves may have disastrous consequences resulting in the loss of life and limb.

- **Mangled extremity:** injury that involve at least  $\frac{3}{4}$  consisting of bone, soft tissue, vessel, nerves

## CLINICAL FEATURES

### ⚡ Soft signs:

- Significant hemorrhage by History
- Small non expanding hematoma
- Decreased pulse compared to the contralateral extremity
- Bony injury
- Wound proximity (1 cm from Vs)
- Neurologic abnormality (anatomically related nerve)

### ⚡ Hard signs:

- Observed pulsatile bleeding
- Ongoing hemorrhage with shock
- Arterial thrill by manual palpation
- Bruit over or near the artery
- Absent distal pulse
- Signs of distal ischemia
- Visible expanding hematoma

## DIAGNOSIS

### ⚡ Doppler ultrasound:

- Determine presence/absence of arterial supply.
- Assess adequacy of flow.
- Measure Ankle Brachial Index
  - $ABI < 0.90$  = 87% sensitive, 97% specific for arterial injury.
- Presence of signal does not exclude arterial injury!

- In absence of hard signs, can substitute this for screening arteriography.

#### ⚡ **Duplex ultrasound** reliable for:

- Injury to arteries and veins
- A-V fistulas
- Pseudoaneurysms
- Thrombosis
- It has 95% sensitivity & 99 % specificity

#### ⚡ **CT angiograph:**

- Faster, less expensive and less invasive
- 90-100 % sensitivity and 98% - 100 % specificity
- diagnostic study of choice
- Limitations:
  - difficulty differentiating spasm from occlusion
  - artifact from high attenuation structures like bullet fragments or other foreign matter.

#### ⚡ **Angiography**, indicated in:

- hemodynamic stability.
- Uncertain diagnosis (soft signs/PVD)
- Unclear location

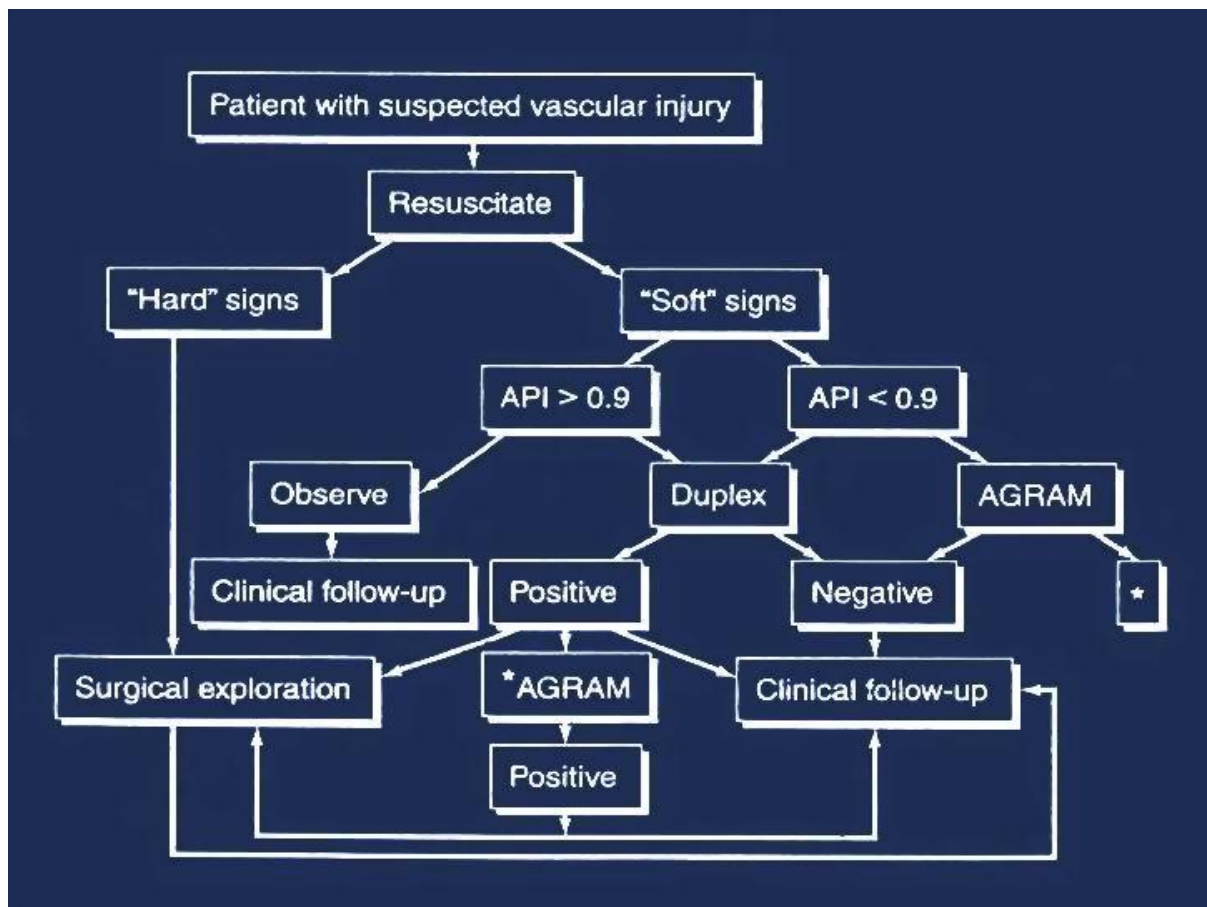


## **TREATMENT**

#### ⚡ **ABCs, then:**

- Control bleeding (Stable, good limb viability → may investigate)
- Replace volume loss
- Cover wounds
- Reduce fractures/dislocations
- Splint
- Do not reperfuse dead limb! → amputation

✦ Then we evaluate the limb:



### ✦ Arterial repair:

1. direct arterial repair
2. arterial patch repair
3. interposition graft repair
4. bypass repair
5. ligation

### ✦ Venous repair:

#### 1. Surgical repair:

- Should be repaired in stable patient if technically feasible
- Lateral venorrhaphy, EEA
- Complex repair (PTFE, SVG)
- Before arterial repair (Limb threatening ischemia → Shunt artery → repair vein)

2. **Ligation** is safe alternative especially in unstable patients, complex injuries.

### ✦ **Amputation:**

- Non-viable or non-salvageable limb
- Irreversible limb ischemia
- Safe life before limbs: Amputation can be life saving in life threatening extremity bleeding.

### ✦ **Complications of vascular injury management:**

#### **1. Hemorrhage.**

#### **2. Thrombosis:**

- Most important complication
- Relatively common compared with other complications,
- Perry et al found an early occlusion rate of 9.1%
- Causes:
  - Inadequate arterial debridement
  - A second adjacent injury
  - Residual distal arterial thrombus
  - Severe stenosis at the suture line
  - Undue tension due to significant missing arterial segment
  - Twisting, or too long graft to cause a kink or external compression of the graft.

#### **3. Infection:**

- Primary skin closure in a war wound
- Placement of a vascular graft in an area of established infection
- Inadequate soft tissue debridement in an attempt to conserve tissue for coverage of a vascular repair.
- Inadequate debridement of a damaged vessel.

#### **4. Stenosis:**

- Technical complication.
- Tight suture repair.
- Lateral repair without sufficient remaining wall
- Residual arterial wall damage.
- Tension on the suture line.

#### **5. Other acute complications:**

- Errors in diagnosis
- second associated or adjacent arterial injury
- Improper identification of the arteries may occur
- Edema
- Embolization
- Disseminated intravascular coagulopathies.

## 6. Other chronic complications:

- Chronic pain.
- Decreased function.
- Ischemic changes.
- Systemic complications.
- Arteriovenous fistulas and false aneurysms.
- Arteriosclerotic changes.
- Aneurysmal graft changes.
- hypertension, diabetes, etc.

# Compartment syndrome



## INTRODUCTION

✦ occurs when muscle swells within osteofacial compartment pressure exceed capillary pressure they end up with ischemia,



## CLINICAL FEATURES

✦ Suspect it and diagnose it early.

- A full-blown compartment syndrome can be recognized easily, but it is likely that irreversible damage has already occurred.

✦ Signs & symptoms:

- Pain, aggravated during stretching of the muscle group involved.
- Pressure.
- Paresthesia.
- Paralysis, late manifestation
- Pulselessness very late stages
- Pall



## DIAGNOSIS

✦ Intercompartmental Pressure Monitoring (It becomes above 30-40mmHg)

✦ Serum Creatine Phosphokinase and Myoglobin

- This enzyme indicates muscle necrosis.
- not appropriate for early detection,



- useful to monitor the progression of equivocal syndromes or recently decompressed compartments.

⚡ Pulse Oximetry and Near-Infrared Spectroscopy



## TREATMENT

⚡ **Fasciotomy:** to fully decompress all involved compartments is the definitive treatment for ACS in the great majority of cases. Indications for fasciotomy:

- Prolonged hypotension
- Swelling of the extremity
- Extensive soft tissue damage
- Combined venous and arterial injury
- Combined bony plus arterial or venous injury or both
- Delay between injury and definitive repair
- Compartmental pressure 35 mm Hg

⚡ **Pharmacologic Interventions** (Mannitol)

# Femoral artery injury



## INTRODUCTION

⚡ 70% of all arterial

- More than 90% penetrating
- Injuries to the femoral artery are not commonly associated with fractures of the femoral shaft.



## TREATMENT

⚡ **Surgical repair:**

- proximal injuries it is wise to initially expose the distal common iliac vessels through a separate incision control before entering the femoral triangle.

- The length of the sterile field includes the entire abdomen to the toes in both lower
- bleeding can be controlled by direct pressure from the source of bleeding
- Blind clamping is strongly discouraged.

✦ **Associated Venous Injuries:** In combined arterial and venous injuries, the vein is repaired first

- The only proven benefit of venous ligation is reduced operating time
  1. improved patency of associated arterial repairs because preserved venous patency maintains normal distal vascular bed resistance, thus optimizing blood flow and reducing stagnation.
  2. reduced incidence of chronic venous insufficiency and associated postphlebotic syndrome.
- Autogenous saphenous vein graft is the conduit of choice
- polytetrafluoroethylene can be used with good results
- If vein ligation is performed, early fasciotomy is indicated

## Popliteal artery injury



### INTRODUCTION

✦ 12% of all arterial injuries

- the civilian sector has provided the bulk of experience with these injuries.
- blunt mechanisms account for 20% to 75% of all cases.



### DIAGNOSIS

✦ Most cases present with “hard” signs of vascular injury → clinical picture diagnosis.



### TREATMENT

✦ Surgical Repair

- Medial longitudinal incision placed 1 cm posterior to the distal femur and proximal tibia
- End-to-end anastomosis
- Division of geniculate collaterals to achieve mobility should be avoided

- Prosthetic grafts across the knee joint generally have lower patency rates than does vein and are best avoided
- popliteal vein injuries should be repaired.

## Shank (tibial) vessels injury

### INTRODUCTION

⚡ Management is still controversial.

- uncertainty of the number of patent arteries needed for limb viability.
- Some suggested that ligation of shank vessels is safe as long as one patent vessel remains.
- Others argue that there is a 14% amputation rate after ligation of one of the tibial vessels, 65% after ligation of two vessels,
- any injury to the shank vessels, with the exception of isolated peroneal injury, should be repaired.

### DIAGNOSIS

⚡ hard and soft signs

⚡ (ABI).

⚡ Color-flow duplex

⚡ Angiography.

⚡ Associated injuries:

- thorough neurologic examination
- Associated bony injuries are reported to occur in approximately 35% of cases.

⚡ Occult vascular injuries

- Less than 5 mm intimal disruptions or pseudoaneurysms
- Adherent or downstream protrusion of intimal flaps
- Intact distal circulation
- No active hemorrhage

# Venous diseases

Venous diseases are very common affecting huge number of people.

- Venous system function:

Return blood to the heart & prevent intravascular volume overload (by vasoconstriction and vasodilation).

- Anatomy of the venous system in lower limb:

Superficial system → perforators → deep system.

## Superficial venous system:

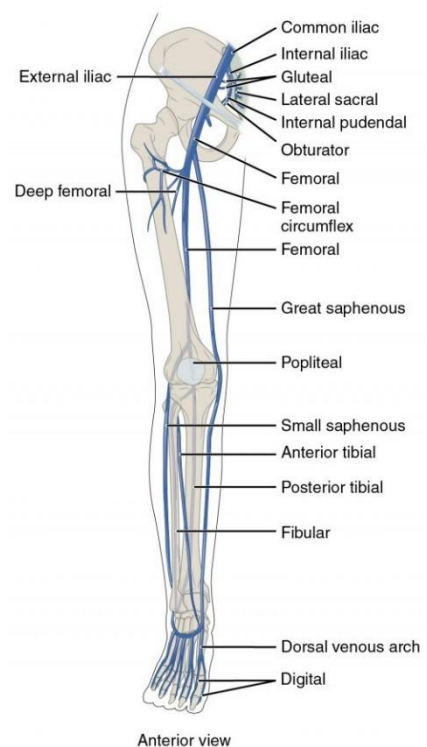
Veins outside the deep fascia and drain the skin and superficial tissues. These are:

- 1- medially placed great (long) saphenous vein ( which drains the dorsum of the foot to the saphenofemoral junction in the groin )
- 2- Small (short) saphenous vein which drains the lateral aspect of the lower limb into the popliteal vein .

## Deep venous system:

This comprises a network of veins lying deep to the deep fascia that envelops the muscular compartments.

Smaller tributaries drain into > popliteal vein > femoral vein > external iliac vein > common iliac > IVC > right atrium.



## MORE ANATOMY:

*The great (long) saphenous vein passes anterior to the medial malleolus at the ankle, up the medial aspect of the calf to behind the knee, then up the medial aspect of the thigh to join the common femoral vein in the groin at the saphenofemoral junction.*

*The lesser (short) saphenous vein passes behind the lateral malleolus at the ankle and up the posterior aspect of the calf. It commonly joins the popliteal vein at the saphenopopliteal junction, which usually lies 2 cm above the posterior knee crease*

**PERFORATORS** communications between superficial and deep veins with valves allowing blood in the superficial system to pass into the deep, and preventing back flow of blood from deep to superficial. Mostly found above the medial malleolus -i.e. gaiter area- (that's explain why venous ulcer mostly found there).



## PATHOPHYSIOLOGY

in a normal vein, the blood flows from the foot up to the heart via the action of muscle contraction ( calf pump ) and backward blood flow is controlled by competent valves (which found every 5 cm and close when the muscle is relaxed ) , these valves are very thin easy to be incompetent leading to increase venous pressure.

incompetent superficial valves will cause → varicose veins

incompetent deep valves will cause → chronic venous insufficiency “CVI”.

NOTE: Another pathology that may affect superficial veins is: superficial thrombophlebitis which is usually secondary to:

- 1- Putting cannula for more than 4-8 hours; especially if it contains 1- cytotoxic drugs as chemotherapy And 2- k+ (KCl ) .
- 2- Varicose veins could lead to it.

## \*\* varicose veins \*\*

**Definition:** abnormally **dilated**, tortuous incompetent veins at any level of the lower limb.



## ETIOLOGY

**Classification:** primary valve defect or secondary to other pathology as previous DVT.

**Risk factors:** 1- FATTY FEMALE ( obesity and female gender ) .

2- pregnancy (as a result of: (1) pressure of the enlarged uterus on the iliac veins(2) due the relaxation of smooth muscle under the influence of hormones).

3- pelvic obstruction .

4- family history .

5- occupation ( long standing teachers and doctors ) .

6- wearing constricting clothes .



## CLINICAL FEATURES

- 1- Its may be **asymptomatic** ( just discomfort about the appearance).
- 2- **Pain**.
- 3- **Edema**.
- 4- **Itching** (leakage of materials outside the circulation; causes skin irritation).  
→ Symptoms get worse at the end of the day.

**Complications:** bleeding, ulcer, **phlebitis** (it is a chemical inflammation because it is not caused by bacteria and treated conservatively with NSAID but bacterial infection could happen causing cellulitis around → here we give antibiotics).



## TREATMENT

- 1- **Conservative:** avoid long standing, elevation of foot and wearing compressing stocking.
- 2- **Sclerotherapy** : injection of a material( hypertonic saline ) that causes sclerosis of veins ( injury > inflammation > fibrosis ), it could be done direct or US guided .
  - Foam sclerotherapy: Adding Air to the injected material to inflate the vein increasing the surface area.
  - Sclerotherapy may not be effective with very extensive varicose veins.
- 3- **surgery ; 2 types :**
  - Conventional (ligation of the incompetent valve).
  - Endovascular: *Endovenous laser treatment, Radiofrequency (RF) ablation.*

## **\*\* Chronic venous insufficiency \*\***

**Known as post thrombotic syndrome**, because it's a chronic complication of DVT (occluded veins may subsequently re-canalize but their valves are rendered incompetent).



## CLINICAL FEATURES

&



## PATHOPHYSIOLOGY

It happens as this clinical scenario:

Swelling (**edema**) → **varicose veins** → **hyperpigmentation** → **ulcer**:

- Starting with DVT which resolved but left incompetent valve → increase venous pressure → transduction of fluid → **edema**
- Back flow of blood -by perforators- to superficial system → dilatation of superficial veins → **varicose veins**.
- Hemosiderin accumulation will cause brown **hyperpigmentation**.
- Poor skin nutrition → epithelial damage → **ulcers**.

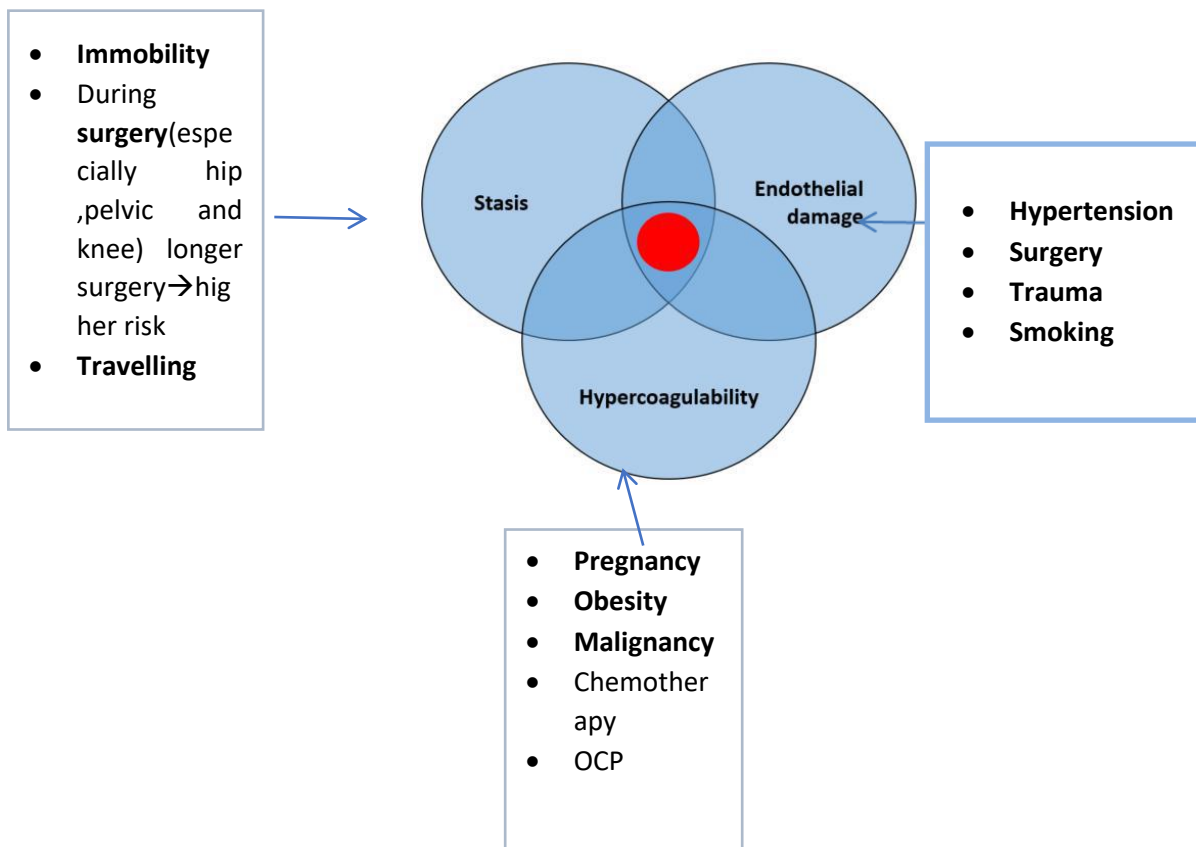


## TREATMENT

- Bed rest.
- Elevation.
- Elastic stocking (many types depend on the pressure).
- For venous ulcer → 4 layers bandage with elevation.

## \*\* Deep Vein Thrombosis \*\*

- Very common and the incidence is increasing over the time, considered as the second cause of death after surgery.
- Risk factors: **VIRCHOWS TRIAD**



→ The most significant risk factor is **previous DVT** then malignancy then major surgery.





## CLINICAL FEATURES

- the patient may present with one of the following:

- 1- The most common presentation of a deep vein thrombosis is pain and swelling, especially in calf – usually in one lower limb; however, bilateral deep vein thromboses are common, occurring in up to 30 per cent. When the swelling is bilateral, deep vein thromboses be differentiated from other causes of systemic edema, such as hypoproteinaemia, renal failure and heart failure.
- 2- Some patients have no symptoms of thrombosis and may first present with signs of a pulmonary embolism, e.g. pleuritic chest pain, haemoptysis and shortness of breath. Patients may also develop shortness of breath from chronic pulmonary hypertension.
- 3- Sometimes the leg appears cellutic and, very occasionally, it may be white or cyanosed: *phlegmasia alba dolens* and *phlegmasia cerulia dolens*.
- 4- Patients who present with venous gangrene often have an underlying neoplasm.

In venogram:  
thrombus is →  
white .  
Blood → black

the

must

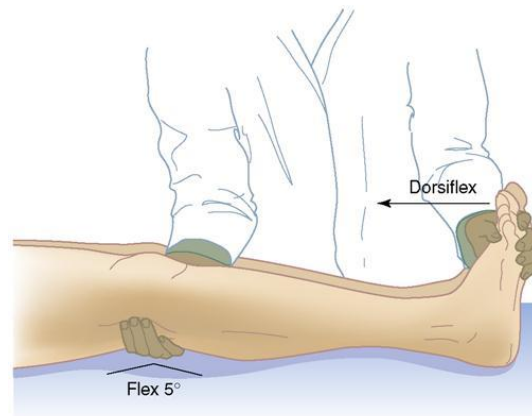
- Physical examination:**

clinical examination for DVT is unreliable. Physical signs may also be absent. Mild pitting oedema of the ankle, dilated surface veins, a stiff calf and tenderness over the course of the deep veins should be sought. Leg pain occurs in about 50 per cent of patients with DVT but is non-specific. Homans' sign -*resistance (not pain) of the calf muscles to forcible dorsiflexion* -is not specific and should not be elicited.

- NOTE: DVT in upper limb associated with fractures , subclavin catheter , Behçet's disease.

- Other differential Diagnosis:**

- 1- **acute** lymphedema (**pitting** edema) .
- 2- cellulitis .
- 3- rupture backer cyst (chemical inflammation).



- **Work up** : history ,physical examination, lab test (D-dimer test ) then dopplur US.

→ We do venogram as late work up because its invasive , could cause allergy due to the use of a constrast .

→ Patient with PE usually come complain of tacypnea , dyspnea, respiratoy alkalosis ,hypoexemia → we do ct angiogram .

D-dimer (or D dimer) is a fibrin degradation product (or FDP), a small protein fragment present in the blood after a blood clot is degraded by fibrinolysis. Used in the diagnosis of thrombosis.

A negative result practically rules out thrombosis, a positive result can indicate thrombosis but does not rule out other potential causes.

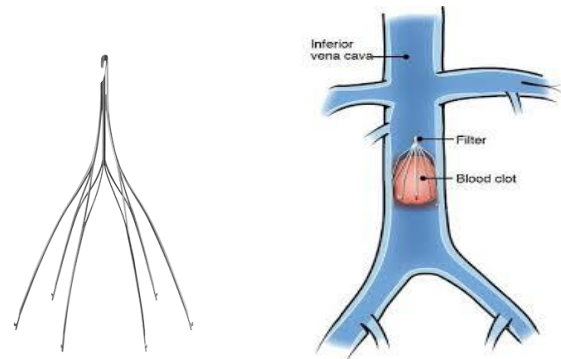


## TREATMENT

Anticoagulant :start with Heparin at least for 2 days → then we give with warfarrin for another 2 days → then we stop heparin and continue with warfarrin for( 3months OR 6 month OR for life (that's depend on the risk factors; eg: someone complains of recurrent DVTs -> for life, protein C deficiency -> for life ).

An **inferior vena cava filter (IVC filter)** is a type of vascular filter, a medical device that is implanted by interventional radiologists or vascular surgeons into the inferior vena cava to presumably prevent life-threatening pulmonary emboli (PEs).Used in cases where patients are at high risk of developing a clinically significant PE and cannot be sufficiently anticoagulated.

It is implanted below the renal vein (to avoid acute renal failure).



# Ulcers; Venous vs. Arterial

6.41 Clinical features of venous and arterial ulceration		
Clinical feature	Venous ulceration	Arterial ulceration
Age	Develops at age 40–45 but may not present for years; multiple recurrences common	First presents in over-60s
Sex	More common in women	More common in men
Past medical history	Deep vein thrombosis (DVT) or suggestive of occult DVT, i.e. leg swelling after childbirth, hip/knee replacement or long bone fracture	Peripheral arterial disease, cardio- and cerebrovascular disease
Risk factors	Thrombophilia, family history, previous DVT	Smoking, diabetes, hypercholesterolaemia and hypertension
Pain	One-third have pain (not usually severe) that improves with elevating the leg	Severe pain, except in diabetics with neuropathy; improves on dependency
Site	Gaiter areas; usually medial to long saphenous vein; 20% are lateral to short saphenous vein	Pressure areas (malleoli, heel, fifth metatarsal base, metatarsal heads and toes)
Margin	Irregular, often with neoepithelium (appears whiter than mature skin)	Regular, indolent, 'punched out'
Base	Often pink and granulating under green slough	Sloughy (green) or necrotic (black), with no granulation
Surrounding skin	Lipodermatosclerosis always present	No venous skin changes
Veins	Full and usually varicose	Empty with 'guttering' on elevation
Swelling (oedema)	Usually present	Absent
Temperature	Warm	Cold
Pulses	Present, but may be difficult to feel	Absent

## Comparison:

### Venous

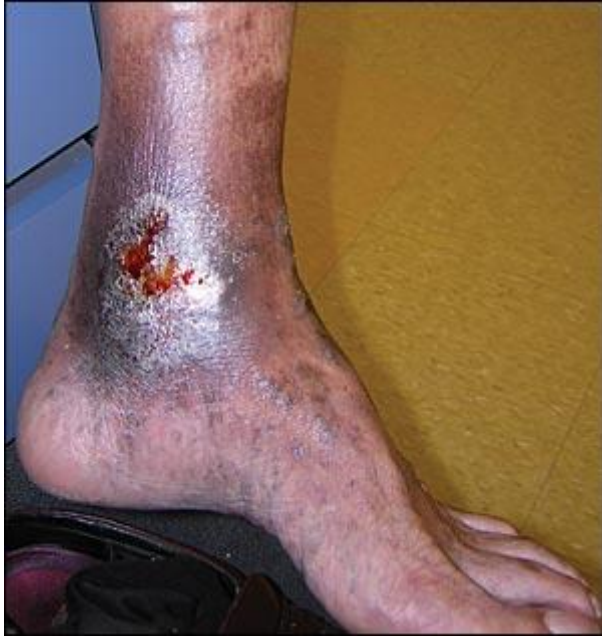- ⌘ Occur on top of chronic venous insufficiency, this entity is characterized by increased venous pressure of the legs due to destruction of the veins following DVT. The leg is swollen due to venous edema. It is accompanied with induration and hyperpigmentation around the ankle. In addition, varicosity of the veins might be noted.
- ⌘ **Edge**: gently sloping.
- ⌘ **Base** may be covered with yellow slough but becomes covered with pink granulation tissue when the ulcer is healing.
- ⌘ **Depth** usually shallow and flat.
- ⌘ The **discharge** is usually seropurulent.

### Arterial

- ⌘ Occur on top of chronic arterial insufficiency due to atherosclerosis of the lower limb. The lower limb should be examined for signs of chronic ischemia: coldness, pallor, dryness, venous gutters, and absent pulses.
- ⌘ **Edge** either punched out, if there is no attempt at healing by the surrounding tissues, or sloping, if the ulcer is beginning to heal). The skin at the edge of the ulcer is usually a blue-grey color.
- ⌘ The **base** of the ulcer usually contains grey yellow slough covering flat, pale, and granulation tissue.
- ⌘ **Depth** : Ischemic ulcers are often very deep. They may penetrate down to and through deep fascia, tendon, bone and even an underlying joint.
- ⌘ **Discharge** may be clear fluid, serum or pus.

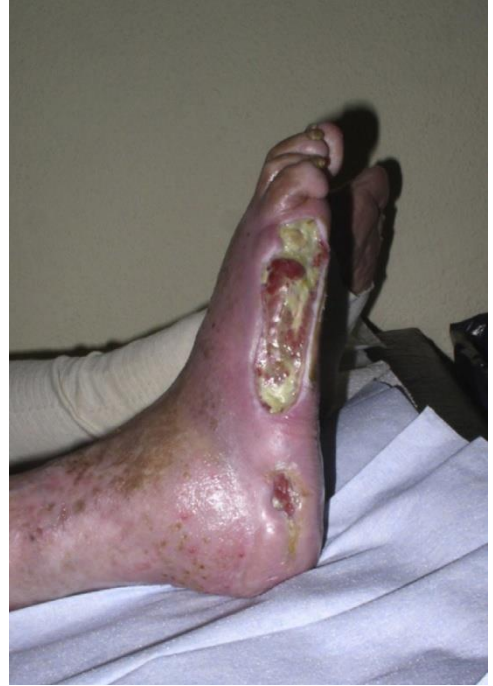- ⌘ **Local lymph nodes:** venous ulcers are usually colonized rather than infected; so the inguinal lymph nodes should **not** be enlarged or tender.
- ⌘ **Special tests:** (Trendelenberg) test/ Perthe's test. (see OSCE dossier)

**Venous ulcer**

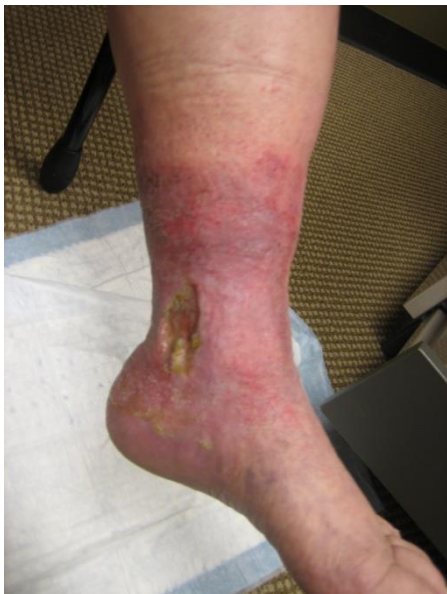

- ⌘ **Local lymph nodes:** Infection in an ischemic ulcer usually remains confined to the ulcer, so that the local lymph glands are **not** normally enlarged.
- ⌘ **Special tests :** Burger test / Ankel to brachial pressure index. (see OSCE dossier)

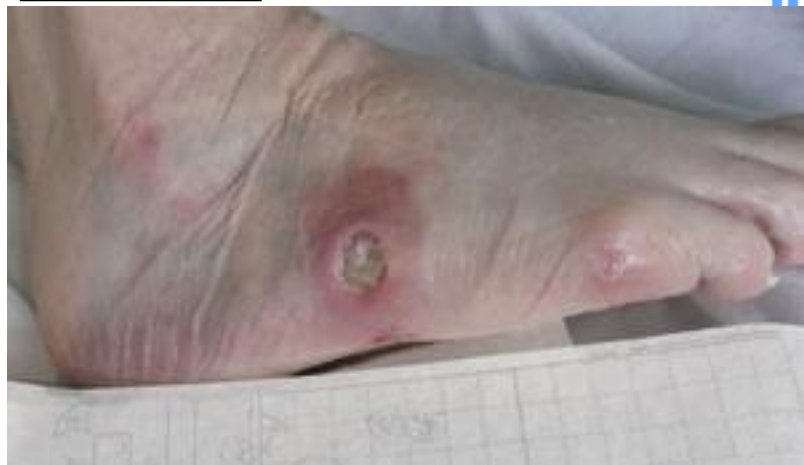**Arterial ulcer**



**Venous ulcer**



**Arterial ulcer**



# Central venous lines & AV fistulae

## 1- Central venous lines

### *a) introduction:*

⌘ Venous access devices that can be implanted under the skin were introduced in 1982. Placement is usually in one of the large veins of the chest or neck, although placement can also be in the groin, if necessary.

- Venous access devices typically remain in place for long periods: weeks, months, or even longer.

### *b) uses:*

⌘ Venous access devices are most often used for the following purposes:

- **Administration of medications** - Antibiotics, chemotherapy drugs, other IV drugs.
- **Administration of fluids and nutritional compounds** (hyperalimentation)
- **Transfusion of blood products**
- **Multiple blood draws** for diagnostic testing

⌘ Venous access devices provide several advantages over regular IV lines, which are usually inserted in a small vein in the hand or arm.

- Venous access devices avoid problems that result over time from administering strong medications through small veins with regular IV lines, namely irritation of the vein and blood clots in the vein.
- A central venous device also avoids the inflammation and scarring that can occur in a vein after multiple needle sticks.
- A central access device increases comfort and reduces anxiety for people who require frequent venous access.

### *C) Common sites for CVL insertion:*

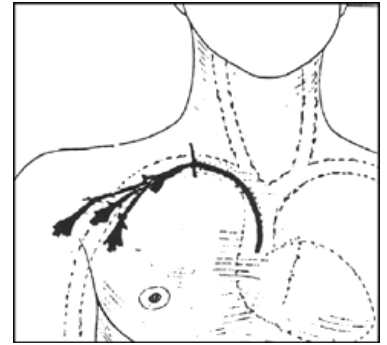
1. Internal jugular vein.
2. Subclavian vein.
3. Femoral vein.



#### *D) types of central venous lines*

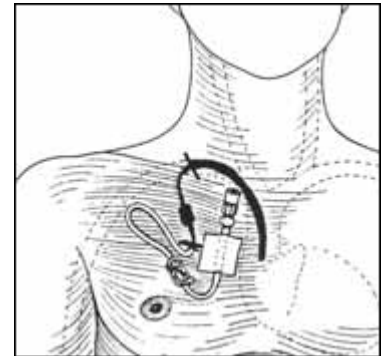
**1. Central – Percutaneous Non-Tunneled Catheter:**

catheter, often with multiple lumens, inserted percutaneously through the subclavian, jugular, or femoral vein.



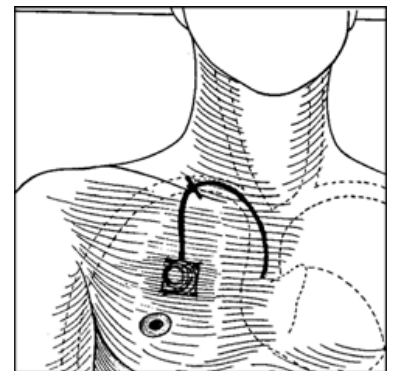
**2. Central – Tunneled Central Venous Catheter:**

Single, double or triple lumen device, surgically tunneled through subcutaneous tissue to an exit site generally on the chest or abdominal wall. The tip rests in the vena cava. A cuff that lies in the subcutaneous tunnel, around which fibrous tissue grows, helps to secure the device.



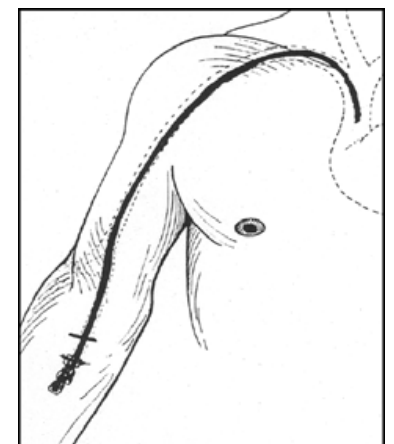
**3. Central – Implanted Port:**

An implanted reservoir generally placed in the chest or arm, attached to a catheter with tip position in the central vasculature. Infusate is delivered to the reservoir via an external non-coring needle and extension tubing



**4. Central – Peripherally Inserted Central Catheter (PICC)**

LA single or double lumen central venous catheter inserted via a peripheral vein – the tip terminates in the superior vena cava (SVC)



#### *E) complications of central venous lines*

- **Pneumothorax & Hemothorax.**
- **Cellulitis** around the catheter or port
- **Catheter infection:** An actual infection of the device itself inside the vein
- **Sepsis.**
- **Mechanical problems.**
- **Venous thrombosis**
- **Endocarditis**

## **2. Hemodialysis (A V) fistulas**

### ***a) introduction***

⚡ Hemodialysis fistulas are surgically created communications between the native artery and vein in an extremity.

- Direct communications are called native arteriovenous fistulas (AVFs).
- Polytetrafluoroethylene (PTFE) and other materials (Dacron, polyurethane, bovine vessels, saphenous veins) are used or have been used as a communication medium between the artery and the vein and are termed prosthetic hemodialysis access arteriovenous grafts (AVGs).

### ***b) Uses:***

- Many patients who are not candidates for renal transplantation or those for whom a compatible donor cannot be secured are dependent on hemodialysis for their lifetime. This situation results in the long-term need for and use of dialysis access.

### ***c) Types:***

1. Radiocephalic Fistula
2. Brachiocephalic Fistula
3. Basilic Vein Transposition
4. Forearm Loop Arteriovenous Graft
5. Upper Arm Arteriovenous Graft
6. Lower Extremity Access Procedure

### ***d) complications:***

1. Infections.
2. Thrombosis.
3. Stenosis.
4. Aneurism.
5. Ischemia of the limb.

**The end of the dossier**



## References

### References

- Bhat M, S. (2016). *Srb's manual of surgery*. [Place of publication not identified]: Jaypee Brothers Medical P.
- BLACKBOURNE, L. (2017). *SURGICAL RECALL*. [Place of publication not identified]: WOLTERS KLUWER.
- Burnand, K., & Browse, N. (2015). *Browse's introduction to the symptoms & signs of surgical disease*. Boca Raton, FL: CRC Press, Taylor & Francis Group.
- Doherty, G. (2002). *The Washington manual of surgery*. Philadelphia: Lippincott Williams & Wilkins.
- halteh, f. (2016). *plastic surgery Dossier*. University of Jordan, Faculty of medicine.
- Latest Medical News, Clinical Trials, Guidelines – Today on Medscape*. (2018). *Medscape.com*. Retrieved 2017, from [http://www.medscape.com/lectures & seminars](http://www.medscape.com/lectures&seminars). (2017). University of Jordan, faculty of medicine.
- Macleod, J., Douglas, G., Nicol, E., & Robertson, C. *Macleod's clinical examination*.
- Matary, M. (2013). *Matary surgery*. egypt: kasr al ainy.
- Smarter Decisions. Better Care..* (2018). *UpToDate*. Retrieved 2017, from <https://www.uptodate.com/>
- Williams, N., O'Connell, P., & McCaskie, A. *Bailey & Love's short practice of surgery*.